



Respiratory System Overview for RN CM/DNs

Debra Ward Goldberg, RN, MSN

DDA SMRO

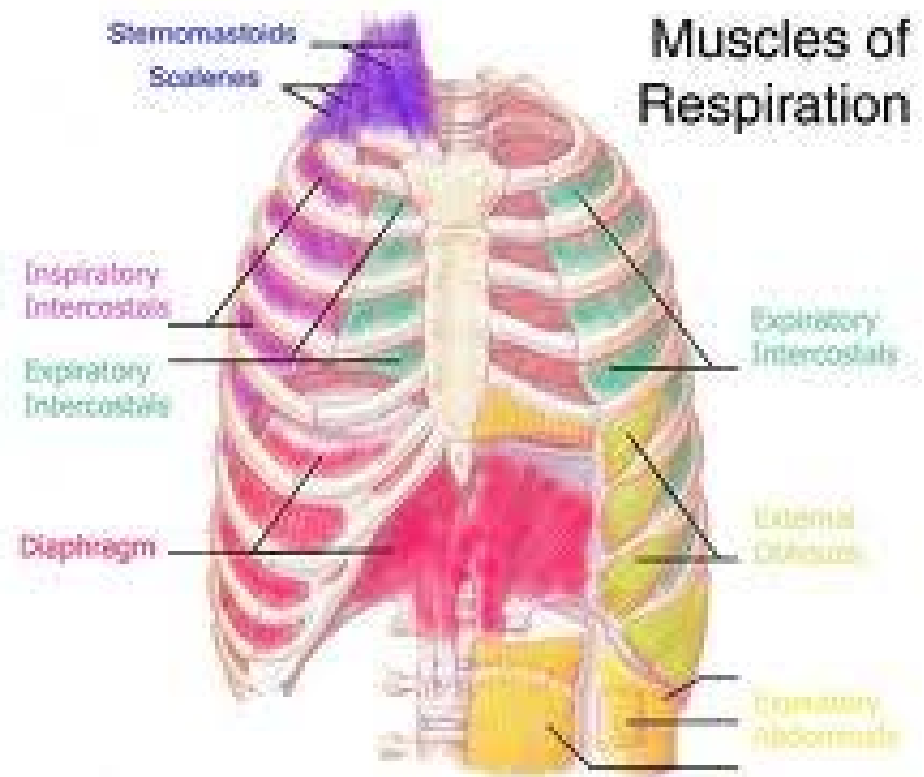
August 2013

- A comprehensive nursing assessment includes an assessment of each system. The purpose of this training is to review the components of a respiratory assessment.

Ventilation

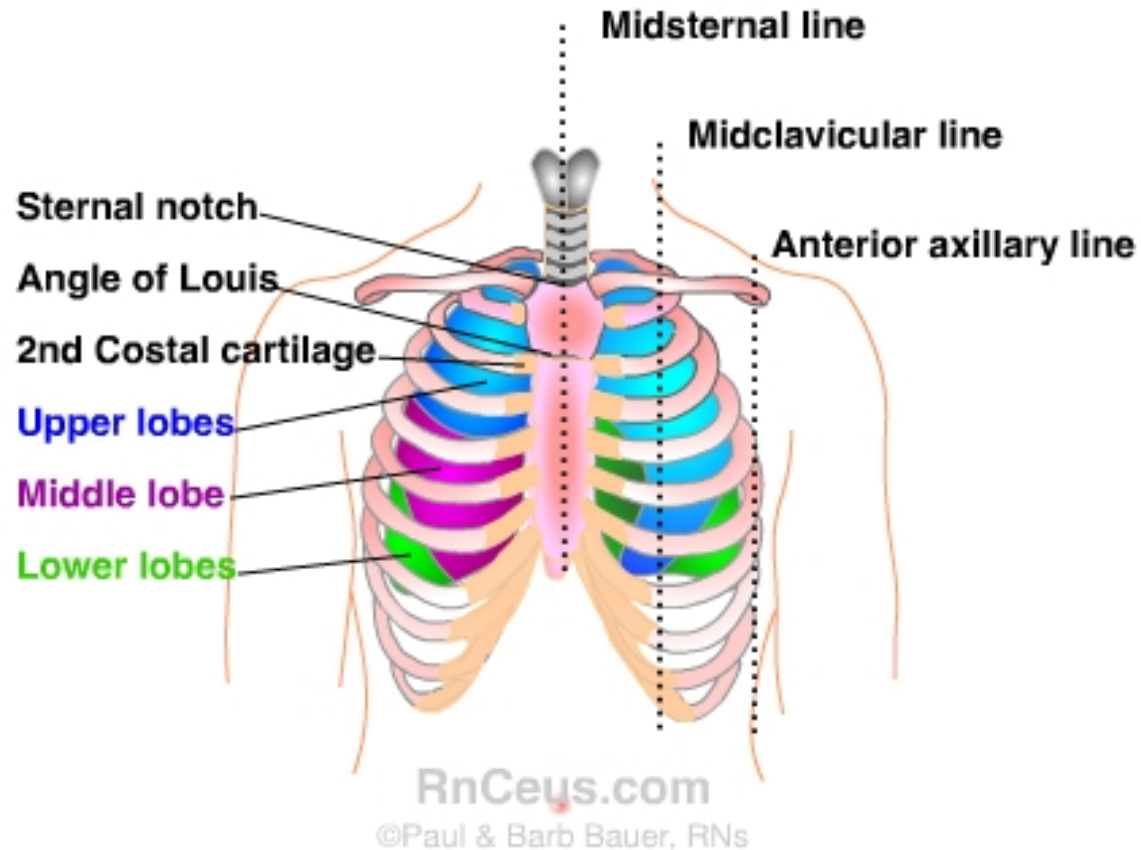
- Ventilation occurs as a result of a mechanical process causing air to move into and out of the lungs.
- The muscles of respiration must overcome any resistance to chest wall movement and lung expansion.

Figure 1.



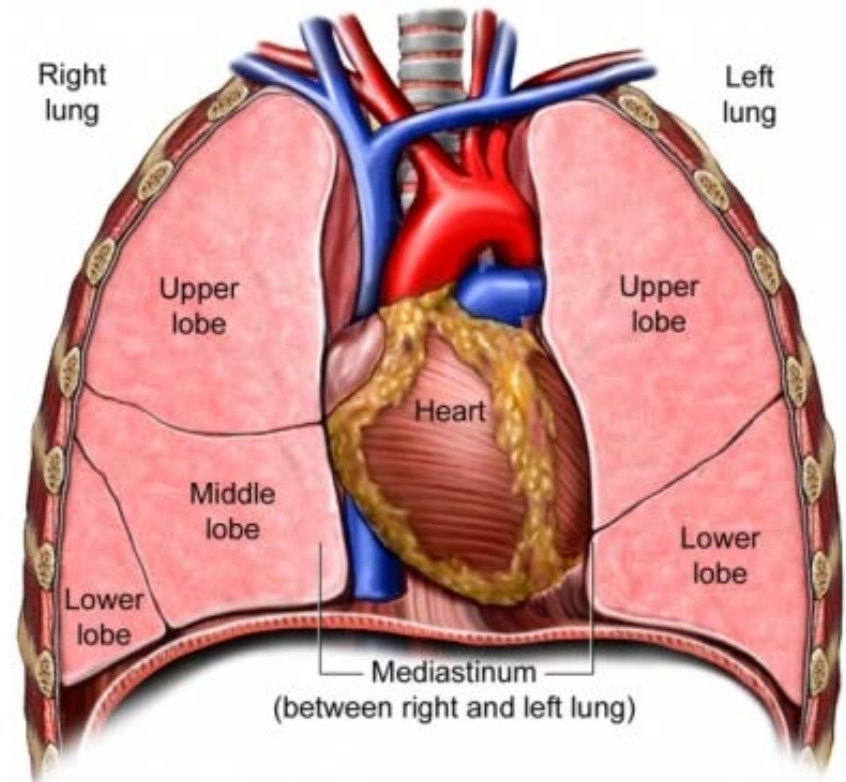
Thoracic Cavity

Anatomic Landmarks



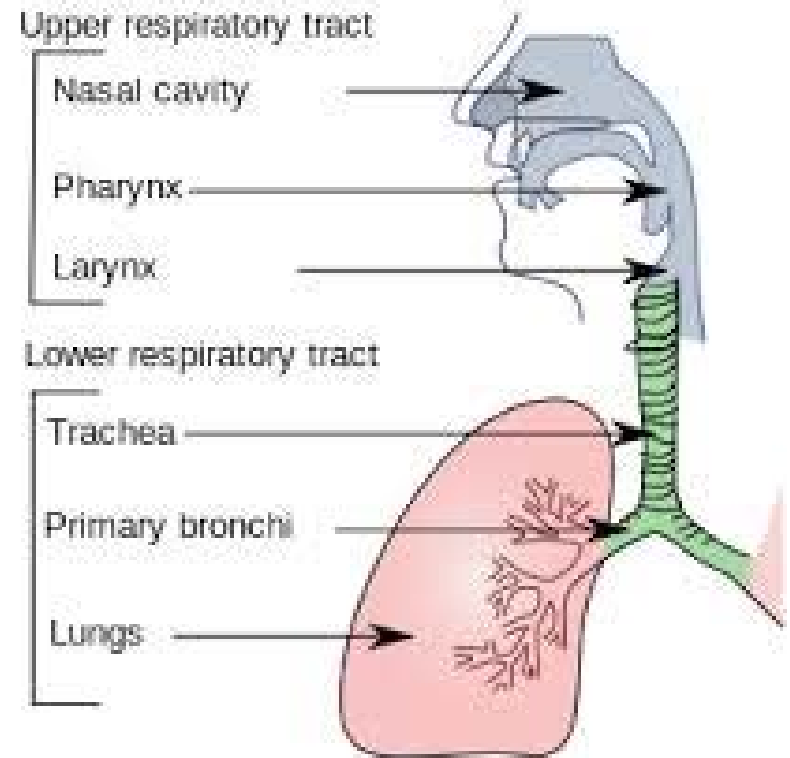
Thoracic Cavity

- Thoracic Cavity:
 - Divided into right and left pleural cavities separated by the mediastinum.
 - Mediastinum contains heart, aorta, lower trachea, large bronchi, esophagus and hilum (where mainstem bronchi and pulmonary vessels enter the lungs)
 - Each pleural cavity lined by pleura (a 2 layer membrane) containing serous lubricating film to facilitate movement without friction.



Upper & Lower Airway

- Upper airway includes the nasal cavity, pharynx and larynx
- Lower airway is comprised of trachea, mainstem bronchi, segmental bronchi, bronchioles, and alveoli.
- Smaller airways obstruct due to mucus/foreign particles.
- Constriction of bronchioles occurs with asthma.
- Aspiration into right lung is more common due to right mainstem bronchus being shorter, wider and more vertical than left.

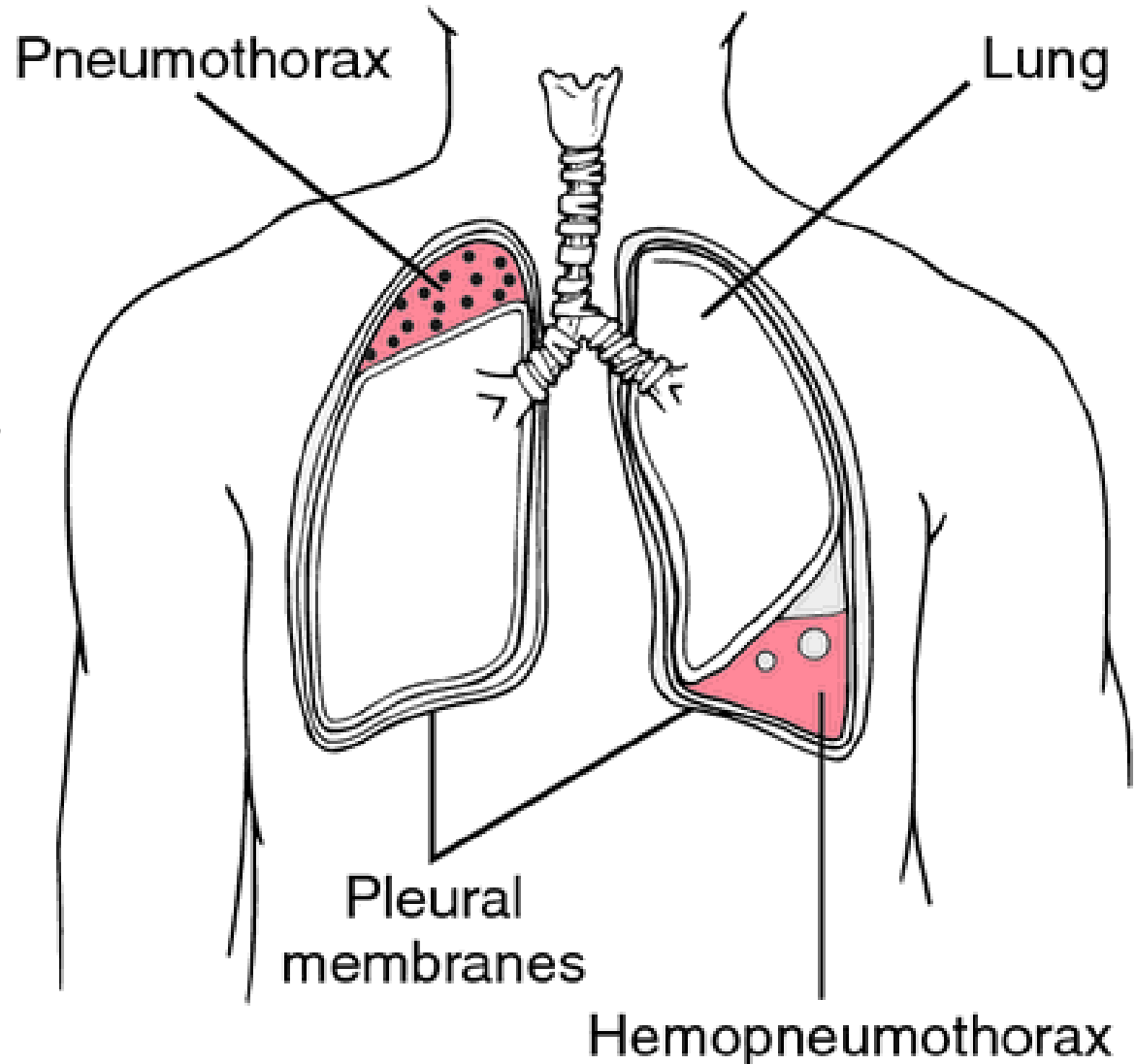


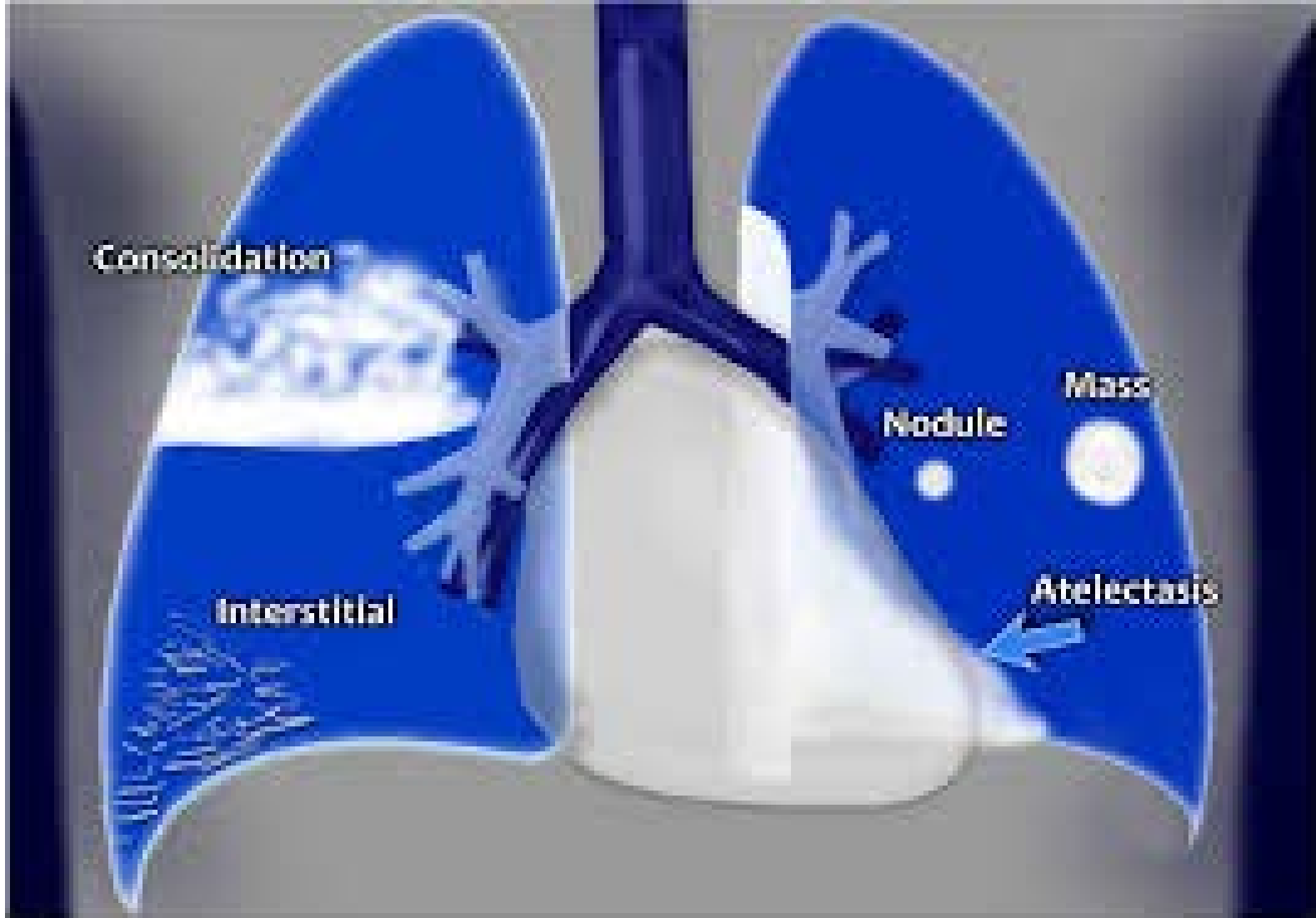
Mechanism of Respiration

- Inspiration:
 - the diaphragm descends and flattens creating a negative intrathoracic pressure that causes air to be “sucked” into the lungs. (Tidal volume)
 - Inspiration is opposed by the elastic properties of the respiratory system.
- Expiration:
 - Passive.
 - The diaphragm relaxes and the elastic recoil properties of the lungs expel air and pull the diaphragm to its resting position.

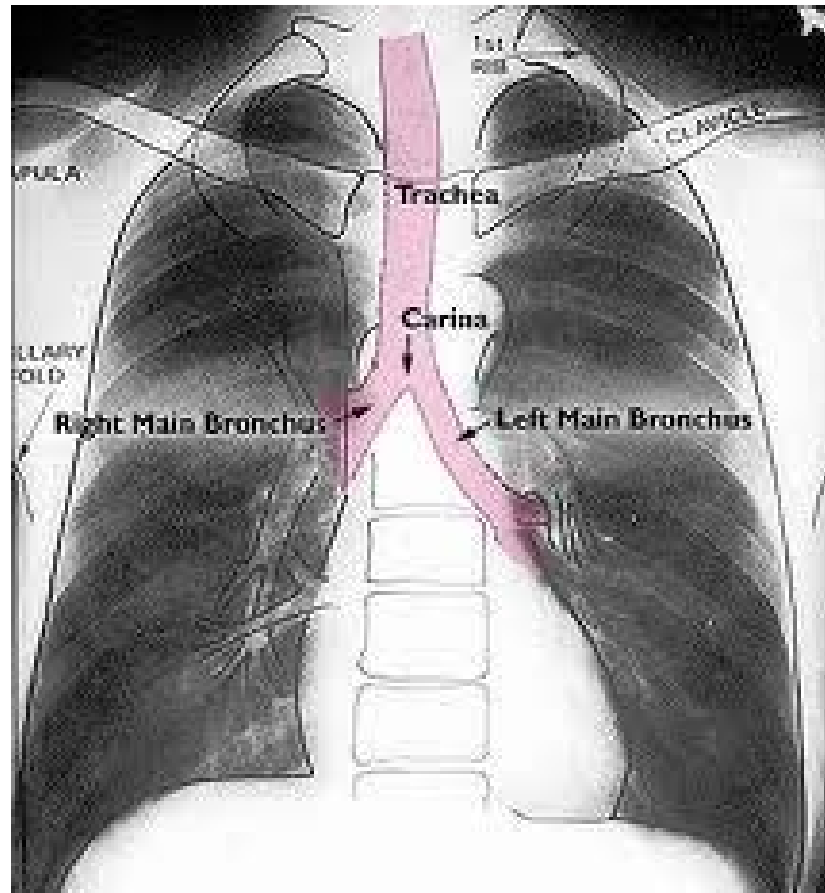
Thoracic Cavity Abnormalities

- Increased pressure within the thoracic cavity (due to pleural effusion, hemo/pneumothorax, empyema, pulmonary edema, tumor) may interfere with expansion.

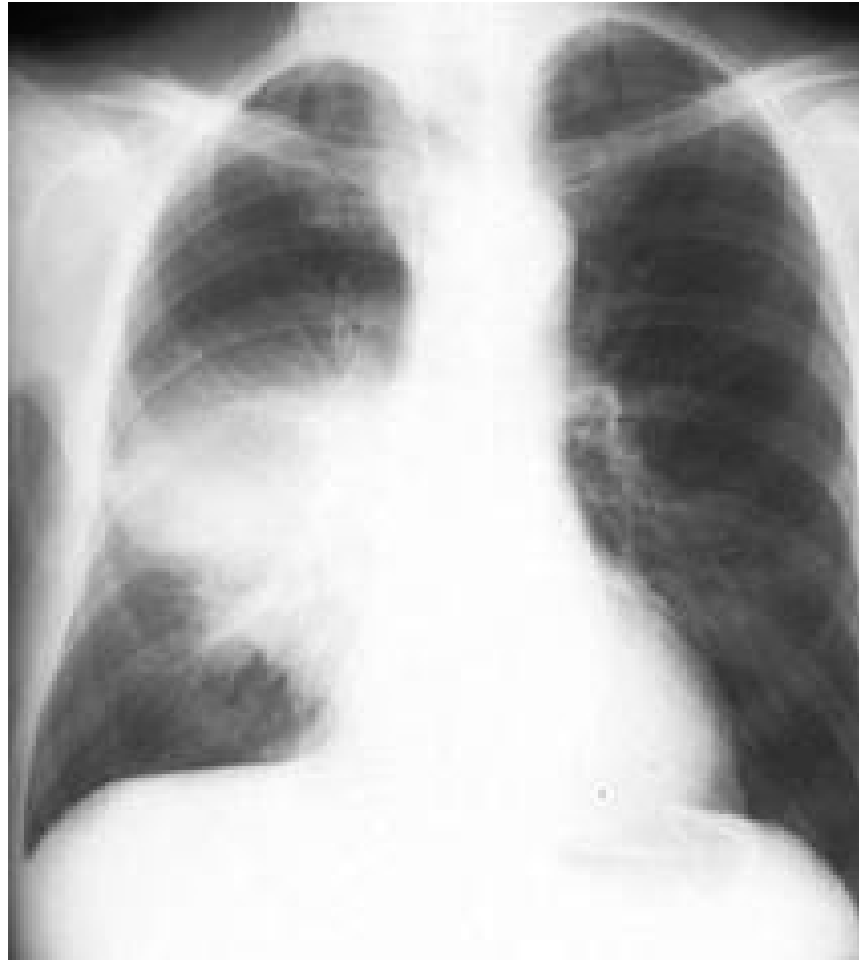



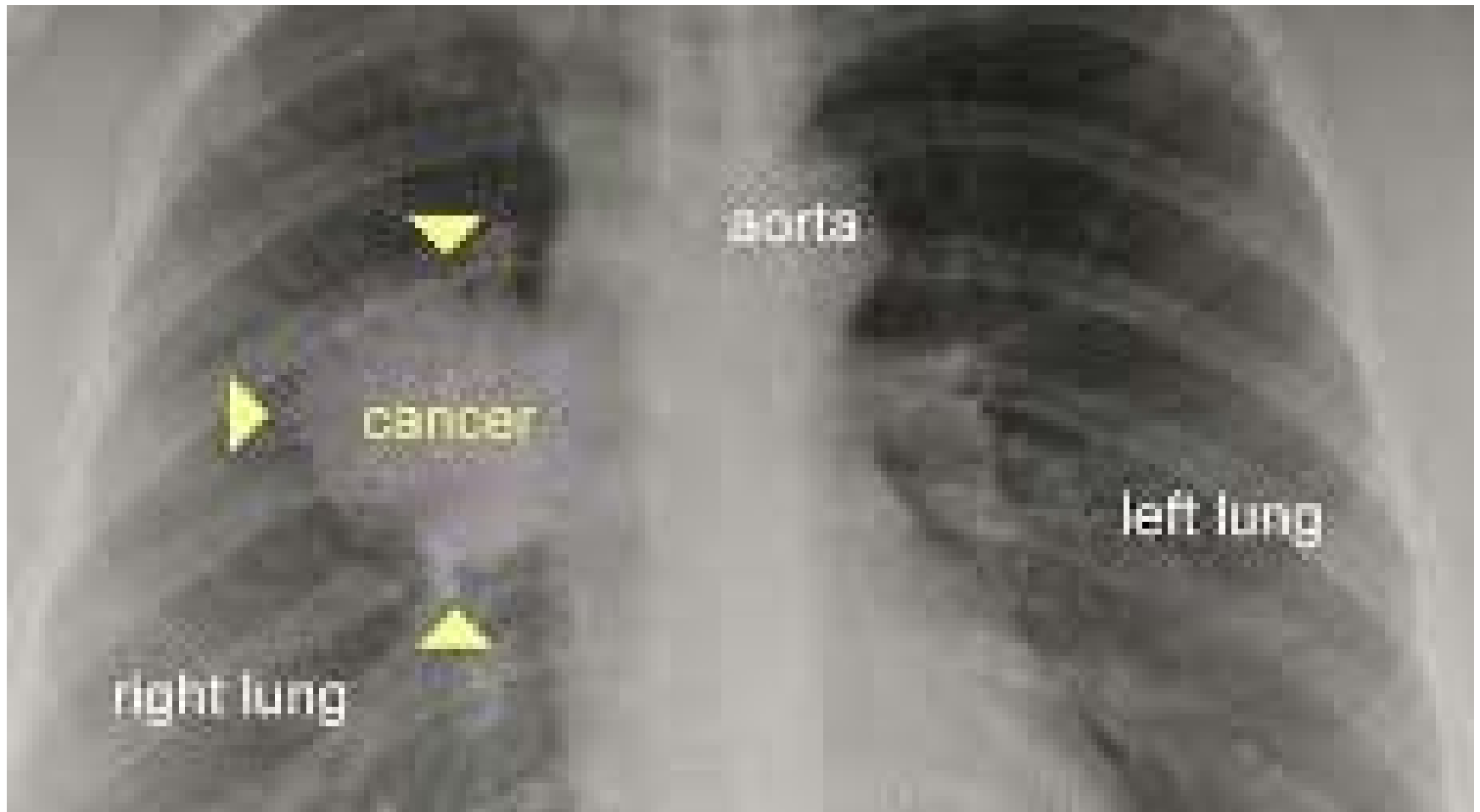
CXR Basics



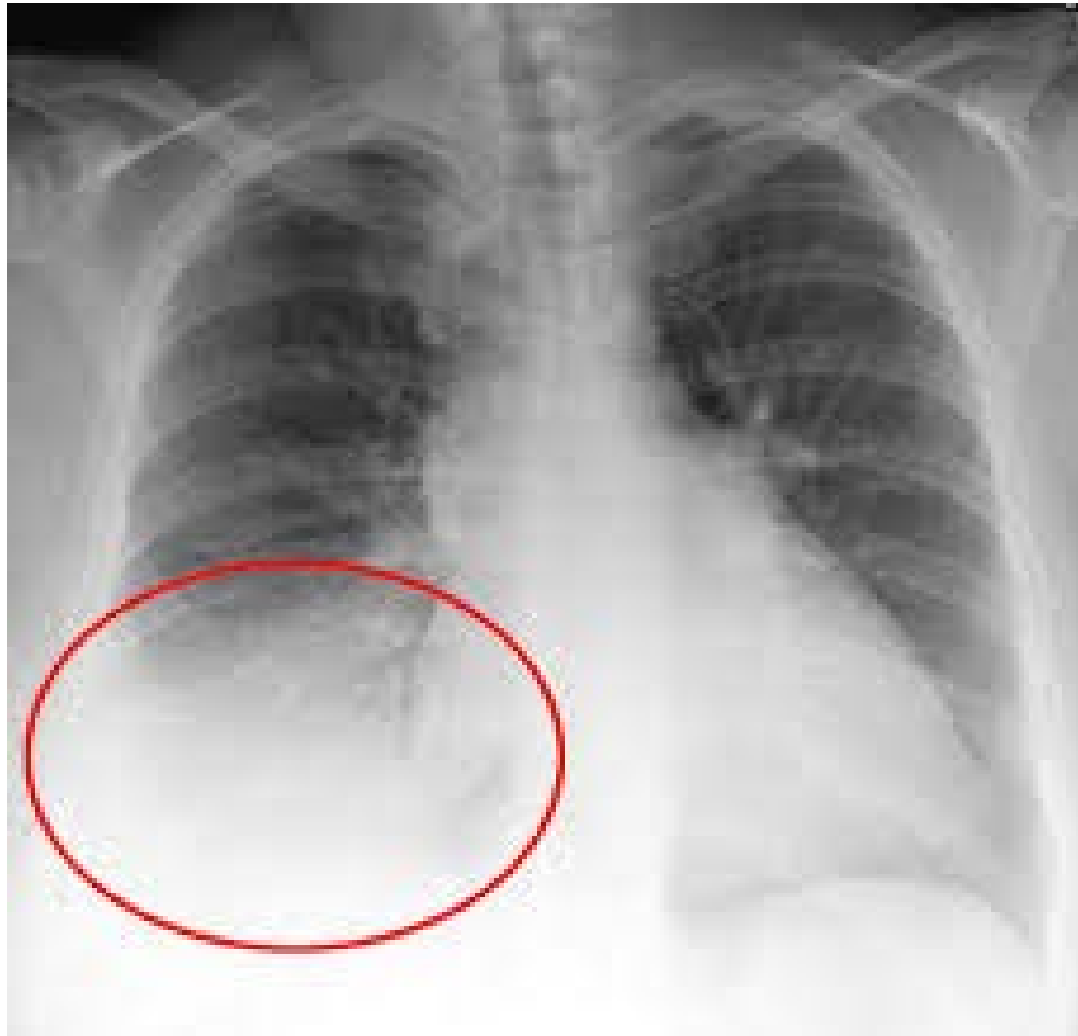What do you see? Aspiration Pneumonia



What do you see? Tumor

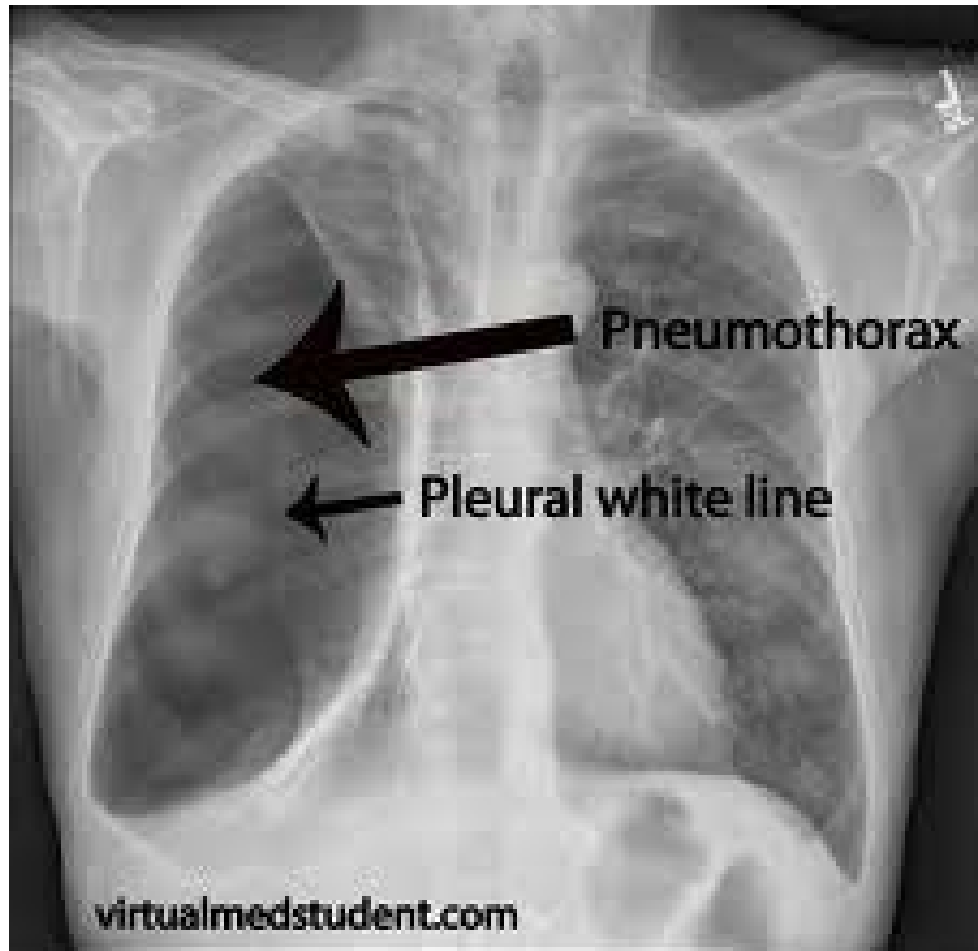


What do you see? Pneumonia



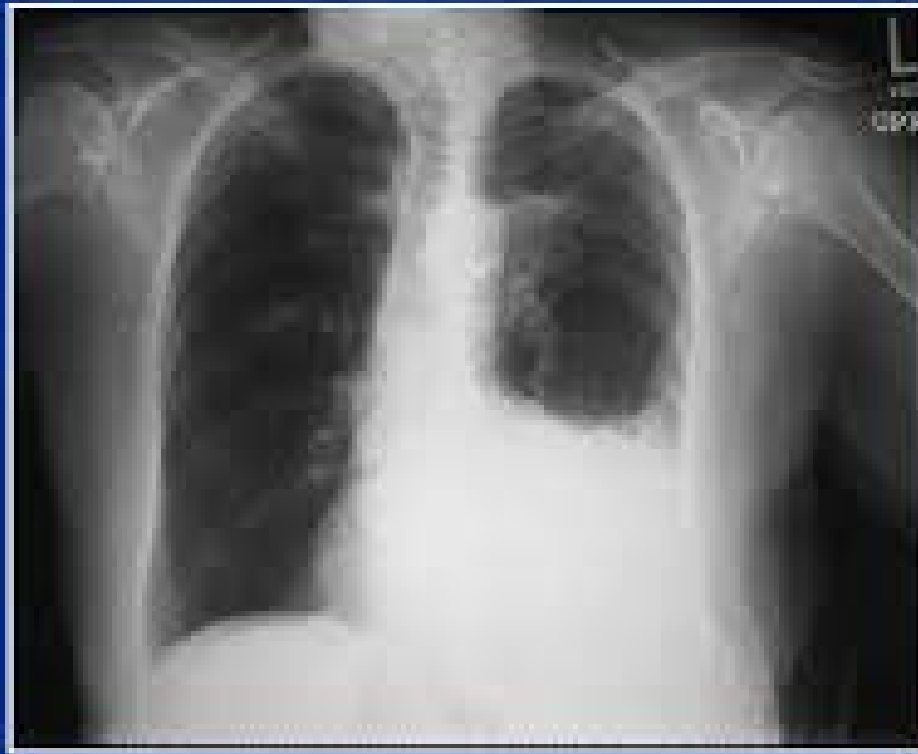http://www.google.com/imgres?q=xray+of+pneumonia&authuser=2&hl=en&biw=1254&bih=645&tbn=isch&tbnid=jDuEcKn6CUap9M:&imgrefurl=http://www.radiologyinfo.org/en/photocat/gallery3.cfm%3Fimage%3Dxray-chest-pneumonia.jpg%26pg%3Dpneumonia&docid=HWMZzeL_DmvpOM&imgurl=http://www.radiologyinfo.org/photocat/popup/xray-chest-pneumonia.jpg&w=450&h=434&ei=aHtMUvfZ06rXyAHrioCABA&zoom=1&ved=1t:3588,r:6,s:0,i:97&iact=rc&page=1&tbnh=183&tbnw=184&start=0&ndsp=19&tx=133&ty=87

What do you see? Pneumothorax



What do you see? Pleural Effusion

Chest X-Ray with Pleural Effusion on the Left



What do you see? Atelectasis

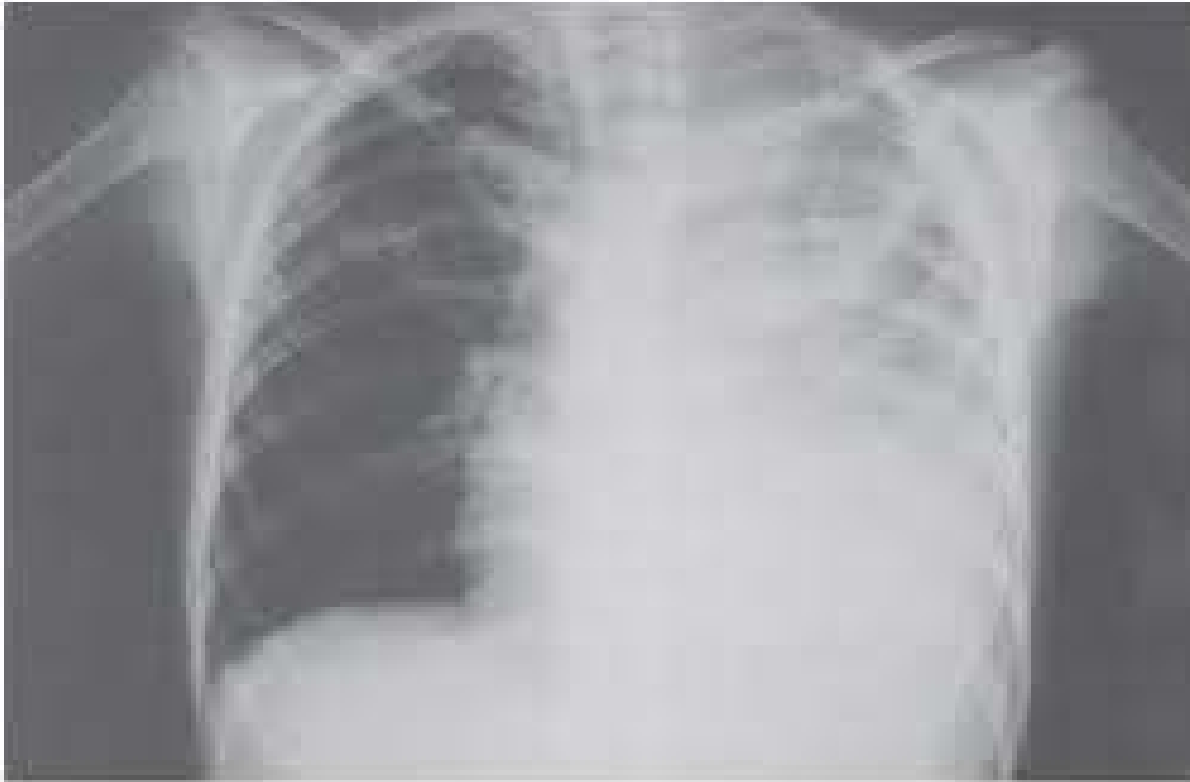
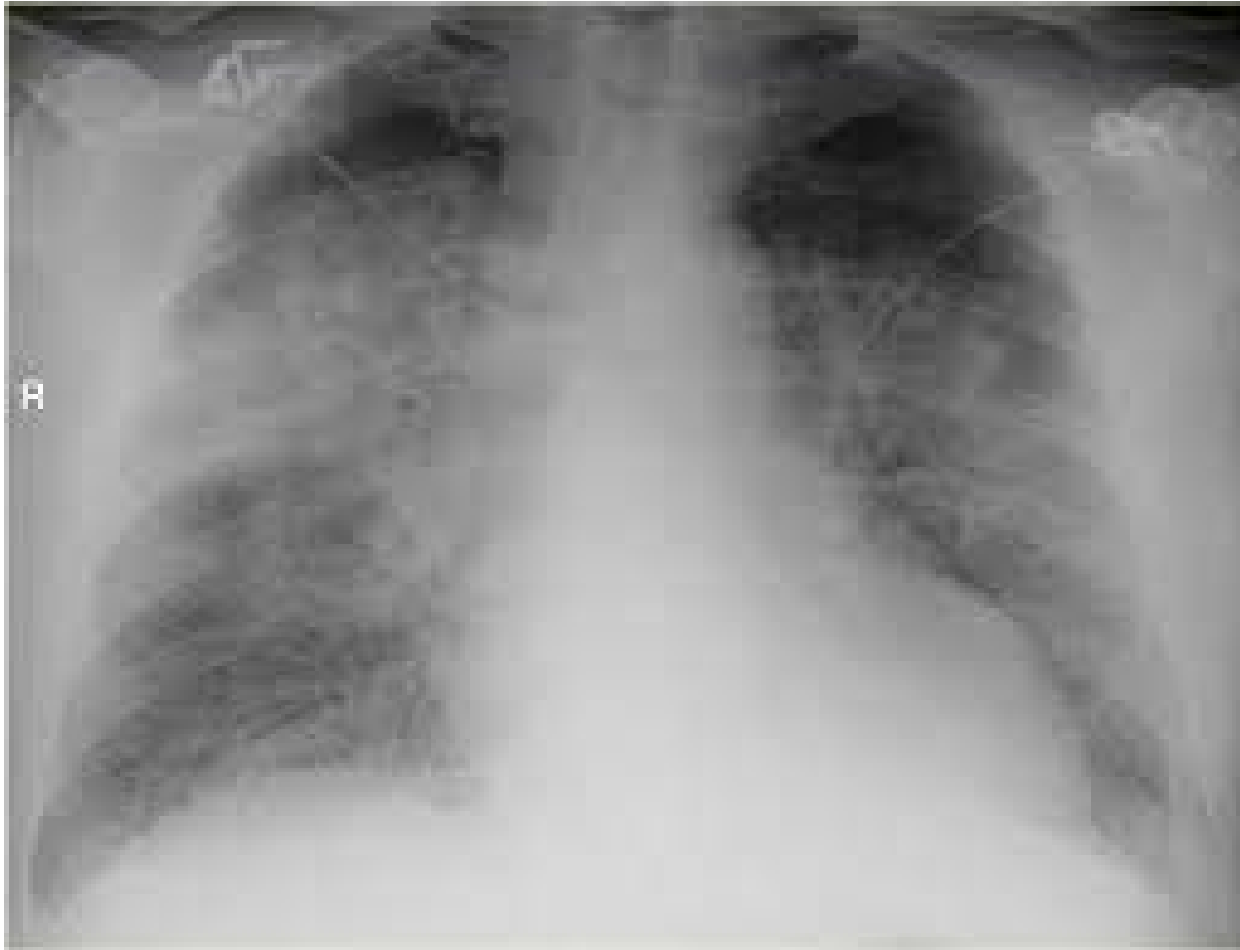
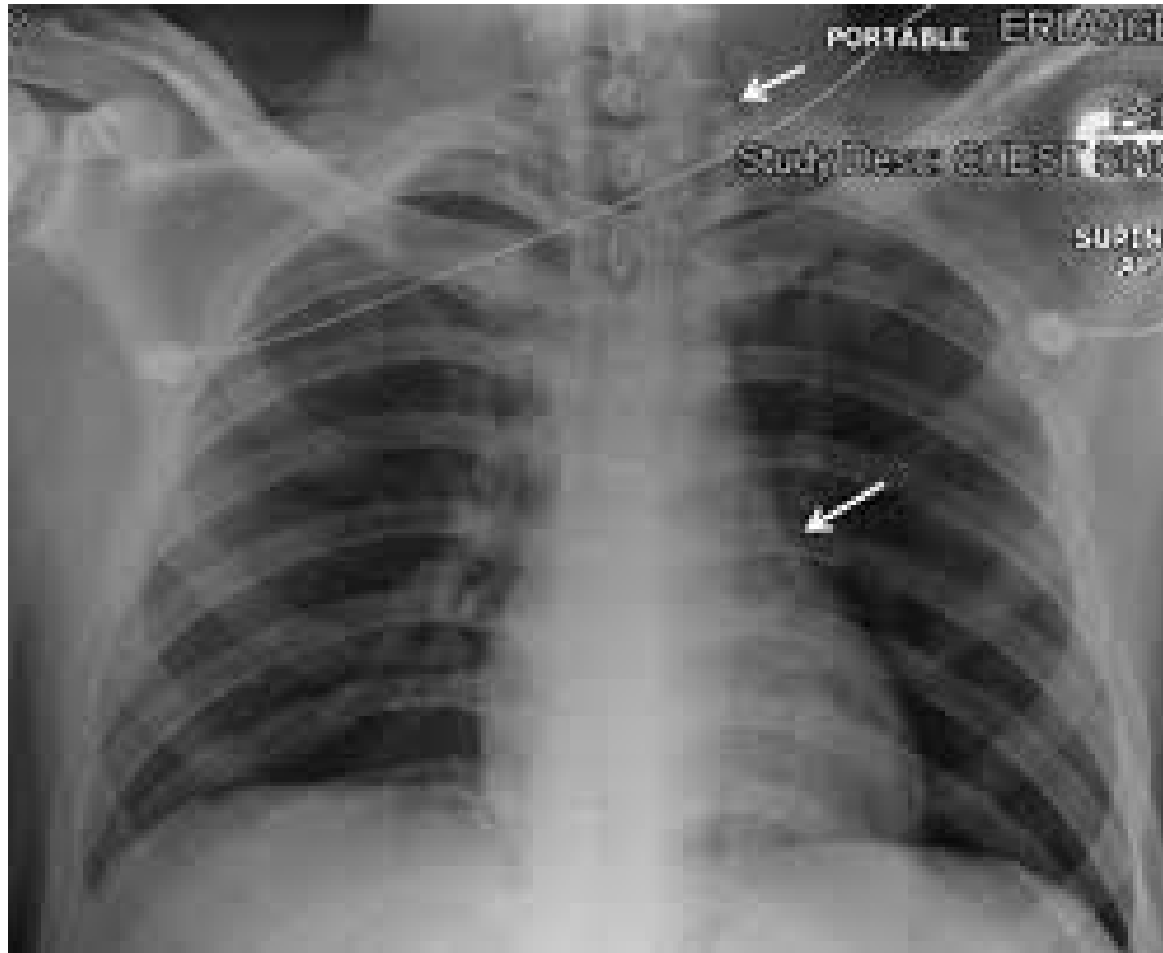


Fig. 1. Homogeneous consolidation and atelectasis on the left lung in the chest X-ray.

What do you see? CHF



What do you see? Emphysema



RESPIRATORY ASSESSMENT

History

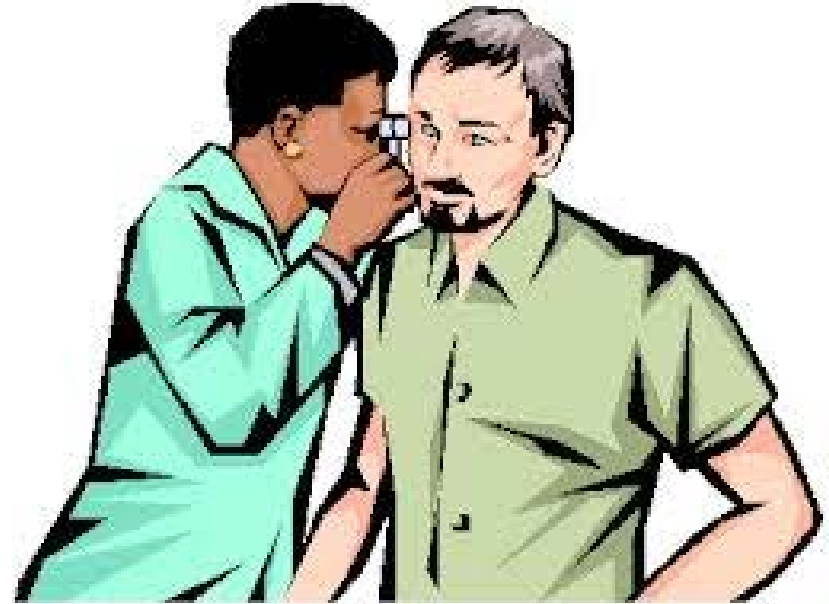- When performing a focused respiratory assessment, the nurse must:
 - 1. determine the chief complaint (onset, symptoms, cough, sputum production, what helps, what makes it worse, pain location/quality),
 - 2. identify elements in the patient's history that relate to the presenting problem (causes, aggravating factors, patient/family hx, life style, smoking, occupational hx, allergens/environment, anxiety) , and,
 - 3. observe the patient.



http://t3.gstatic.com/images?q=tbn:ANd9GcRQOzLtoEz73vsJkNaKMc5BeT0K8yvgNtslnfUvCO_norYfuiFNLg

Physical Exam

- Ensure patient privacy
- Equipment: stethoscope with diaphragm and bell; tubing no more than 18 inches
- Conduct exam in organized progression:
 - **Inspection**
 - **Palpation**
 - **Percussion**
 - **Auscultation**
- Any abnormalities should be identified using anatomic/topographic landmarks.

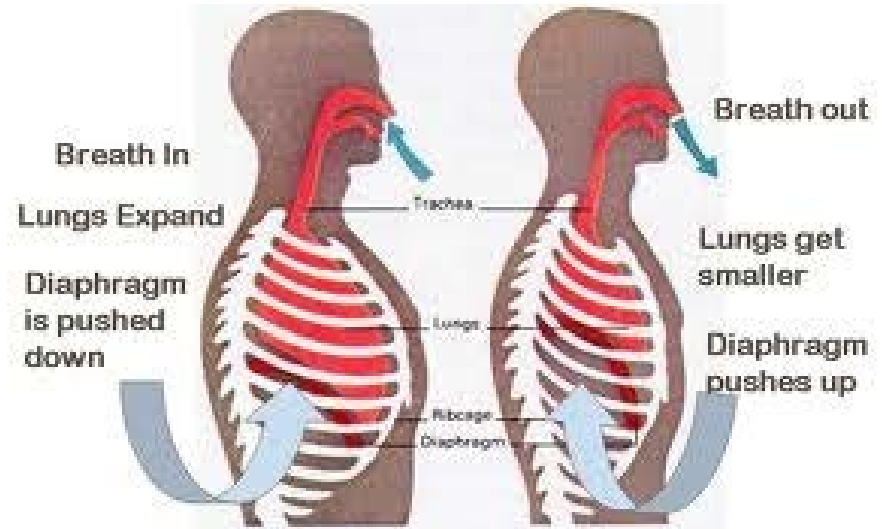


<http://t0.gstatic.com/images?q=tbn:ANd9GcTxgxXLv4E-gYHJrUJbaHFACEAX5VgJ84W6HfEre0QU0PLQNO5I>

INSPECTION

Inspection

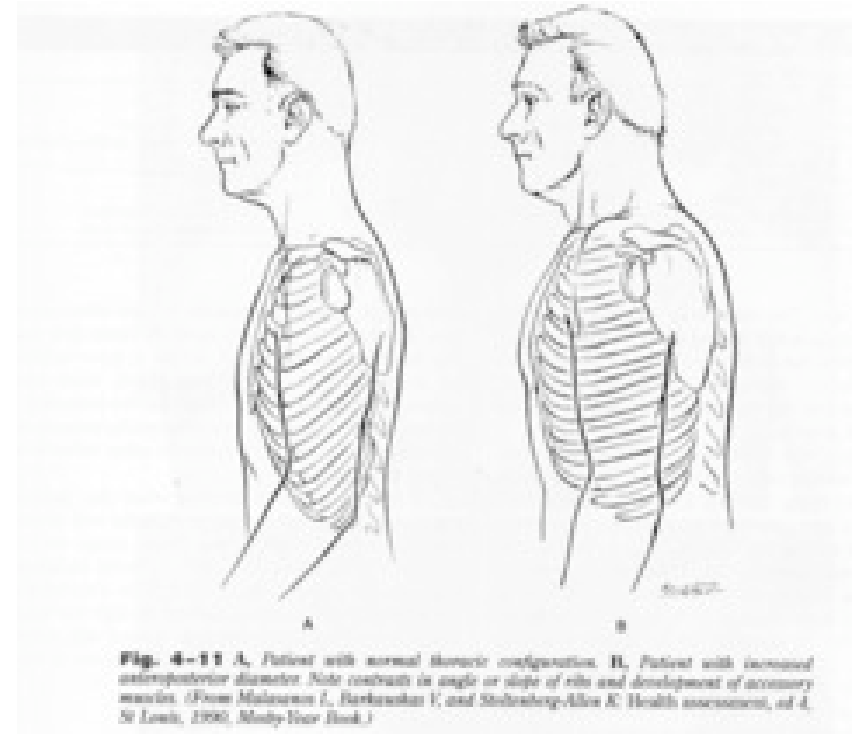
- Observe posture and breathing pattern
 - Slight retraction of intercostals is normal
 - Marked retraction = blockage
 - Forward leaning inhalation position: air hunger
 - Lip pursing: COPD
 - Flaring of nares: air hunger
- Listen for audible breath sounds.
 - Normal rate is 12-20 and smooth and even



http://www.google.com/imgres?q=breathing&authuser=2&hl=en&biw=1254&bih=645&tbnid=M6gn4fRLbjmPOM:&imgrefurl=http://www.daxmoy.com/breathe-your-back-pain-away/&docid=2zBpxsjV_IgHoM&imgurl=http://www.daxmoy.com/wp-content/uploads/2013/08/Breathig.png&w=640&h=388&ei=zYBMUoDWE6LAyAGUVIG4Dw&zoom=1&ved=1t:3588,r:20,s:0,i:156&iact=rc&page=2&tbnh=175&tbnw=288&start=10&ndsp=20&tx=113&ty=87

Inspection

- Note AP to transverse diameter (nl=1:2)
 - Over inflation/COPD:
Barrel chest: AP=2:2
- Inspiratory expansion should be symmetric
 - Asymmetry: collapsed lung, extrapleural air, fluid, or mass
 - Bulging intercostal spaces:
obstruction/emphysema



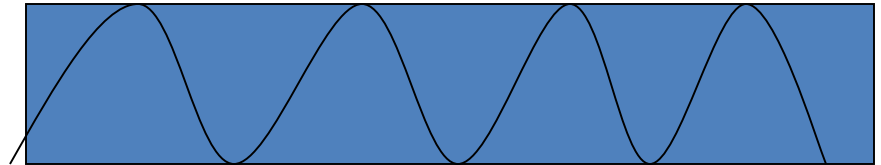
http://www.google.com/imgres?q=ap+diameter+of+chest&authuser=2&hl=en&biw=1254&bih=645&tbnid=jy3FaO7YkmN2M:&imgrefurl=http://quizlet.com/13442992/rt-3025-patient-evaluation-exam-1-study-guide-flash-cards/&docid=aB38E-WdMOtAeM&imgurl=http://o.quizlet.com/y1HU2dBykBOH3TBf0gnLyw_m.jpg&w=240&h=212&ei=PIFMUrKVGsqFyQHv8IGCw&zoom=1&ved=1t:3588,r:15,s:0,i:124&iact=rc&page=1&tbnh=169&tbnw=192&star t=0&ndsp=16&tx=96&ty=130

Inspection: Breathing patterns

Rate/Pattern:

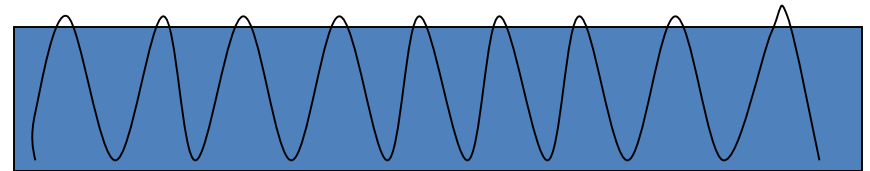
- Eupnea

- Normal
- 12-20 / min




- Tachypnea

- \uparrow rate >20
- Pneumonia, pulmonary edema, acidosis, septicemia, pain



- Bradypnea

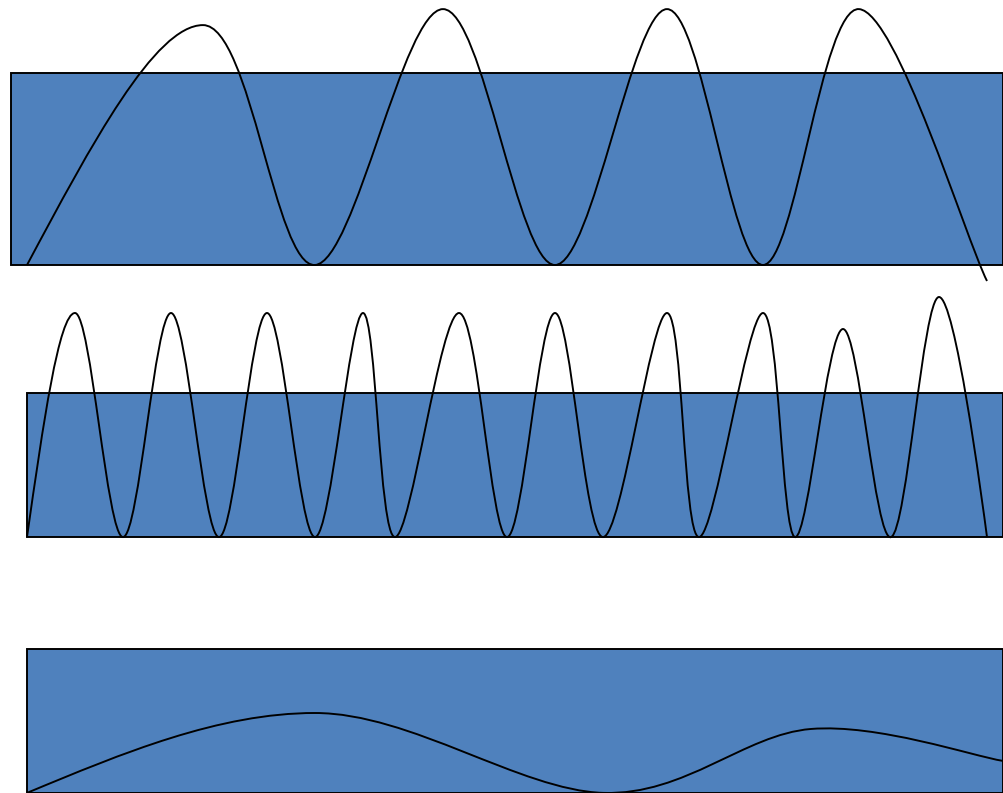
- \downarrow rate <12
- \uparrow ICP, drug OD



Inspection: Breathing patterns

Depth

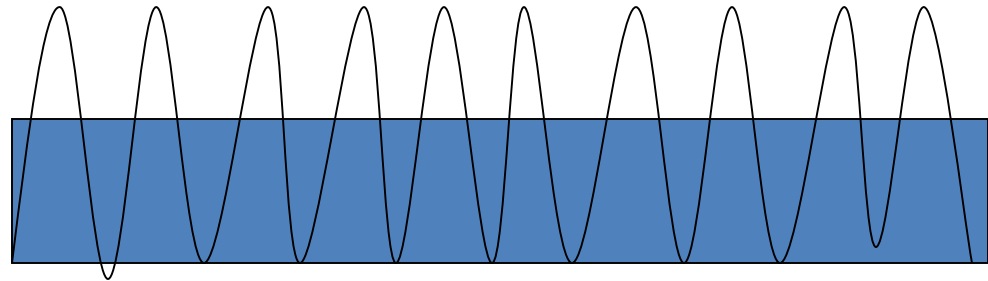
- Hyperpnea
 - \uparrow depth/not rate
- Hyperventilation
 - \uparrow depth & rate
- Hypoventilation
 - \downarrow depth & rate



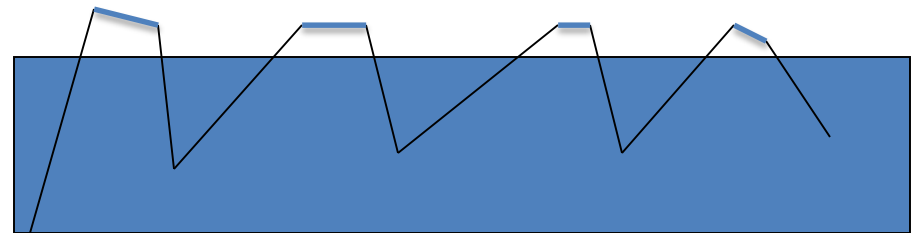
Inspection: Breathing patterns

Depth abnormalities:

- Kussmaul's
 - \uparrow rate & depth
 - Resp compensation for severe acidosis (DKA)



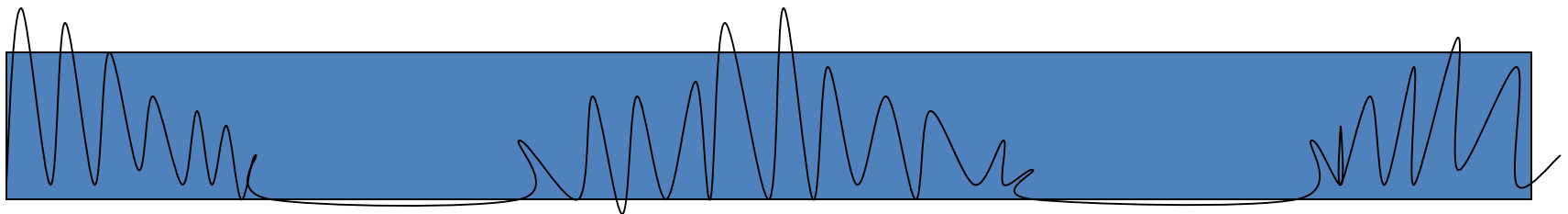
- Apneustic
 - Deep, gasping inspiration with a pause at full inspiration followed by inadequate expiration
 - Brainstem lesion



Inspection: Breathing patterns

Rhythm abnormalities:

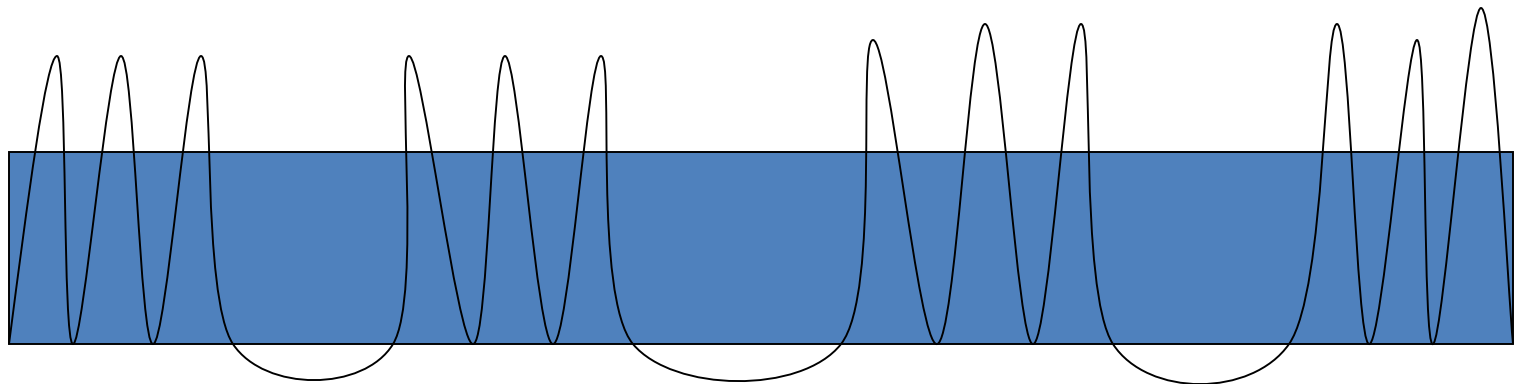
- Apnea
 - Not breathing
- Cheyne-Stokes
 - Varying depth followed by apnea
 - “Death rattle,” Agonal



Inspection: Breathing patterns

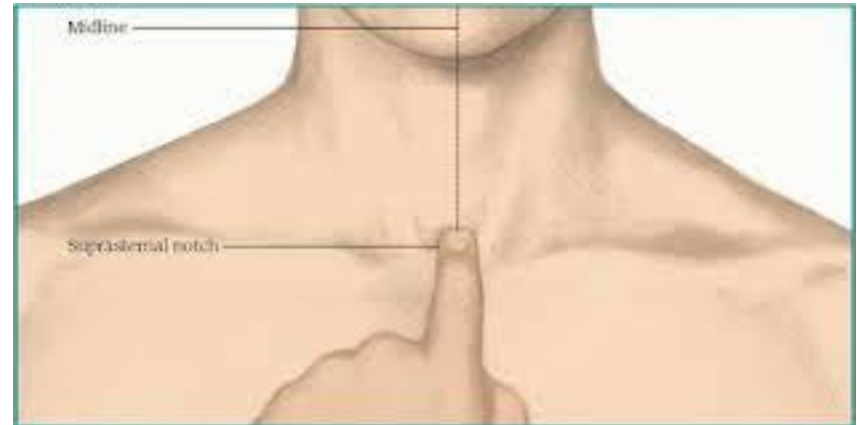
Rhythm

- Biot's
 - ↑ rate & depth w/ abrupt pauses
 - Assoc w/ ↑ ICP; brainstem lesion

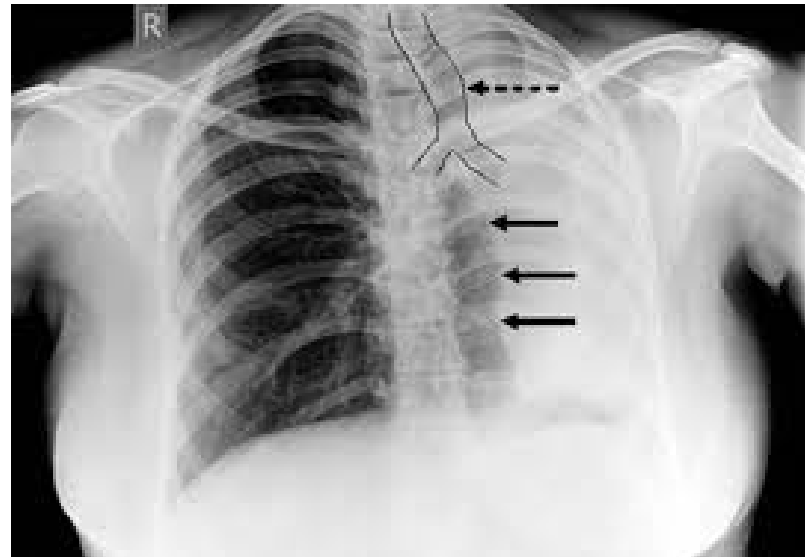


Inspection

- Position of trachea:
 - Normal: central
 - Deviation:
 - Pleural effusion
 - Tension pneumothorax
 - Atelectasis




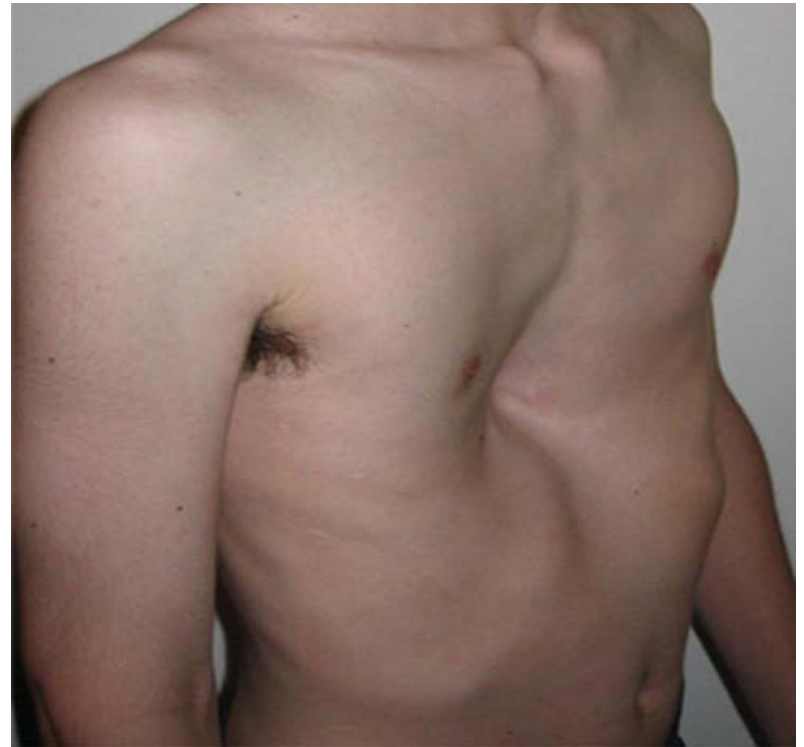<http://t3.gstatic.com/images?q=tbn:AND9GcQoPHKEvV1jycEzP2TcEqgVKmzCd-xm793di4eLiOyLXIO4ZkQXg>



http://t0.gstatic.com/images?q=tbn:AND9GcSuJ7dZ3disDrexrIU7PPXjIh_3xgX0FrLweXN_P8tIn2KAaciw4g

Inspection

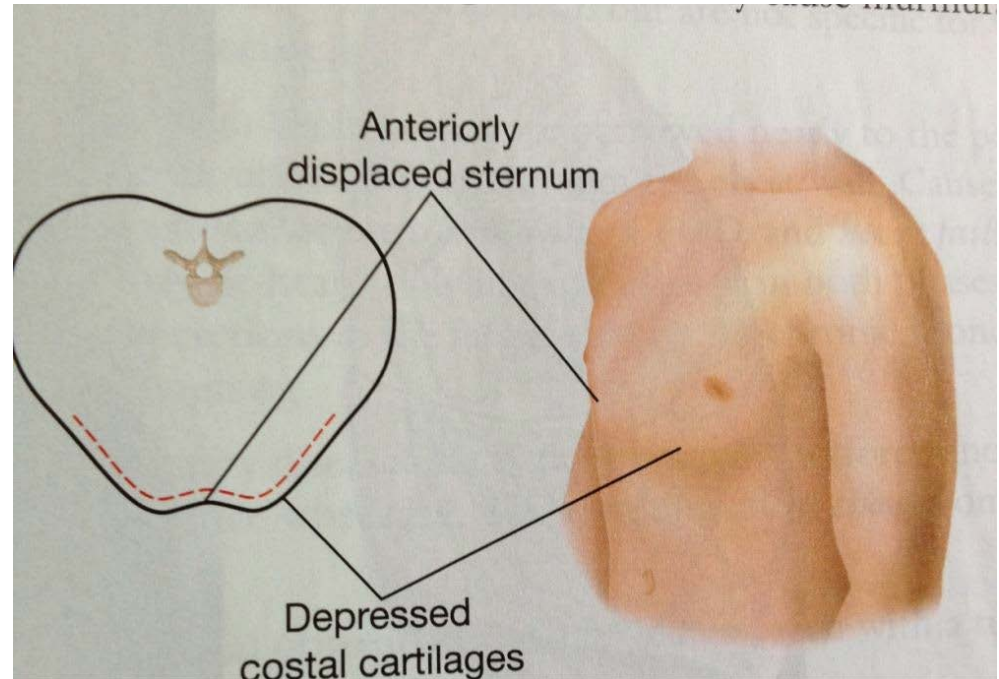
- Funnel Chest/
Pectus Excavatum:
 - depression of
lower portion of
sternum
 - Complications:
heart damage/ 
CO



http://t0.gstatic.com/images?q=tbn:ANd9GcRA9400MKgVzIP0TGQpYBR9ywprYTs mJ-G-_KHenRLcSr2fMCKtzg

Inspection

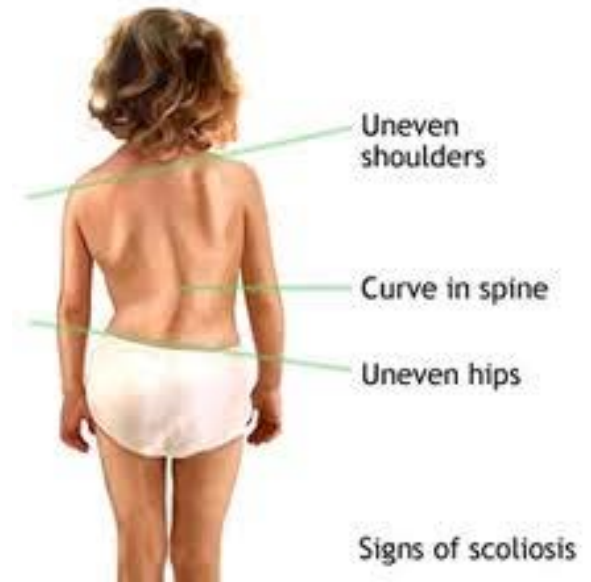- Pigeon Chest/
Pectus Carinatum:
 - sternum protrudes anteriorly
 - Increased AP diameter



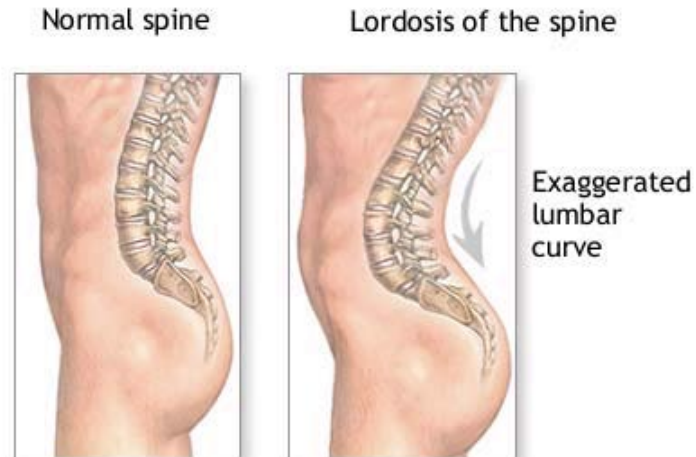
<http://t1.gstatic.com/images?q=tbn:ANd9GcTspozJglusVGtspCxf6y0JgxwNU9ZlaWfToSPdnaNPWbGkzpSz>

Spine Deformities

- Scoliosis: Lateral/rotational curvature of spine →
 - Complications: restrictive lung dx, back problems
- Kyphosis: Hunchback/forward curvature of thoracic spine
- Lordosis: Sway-back; anterior curvature of spine →

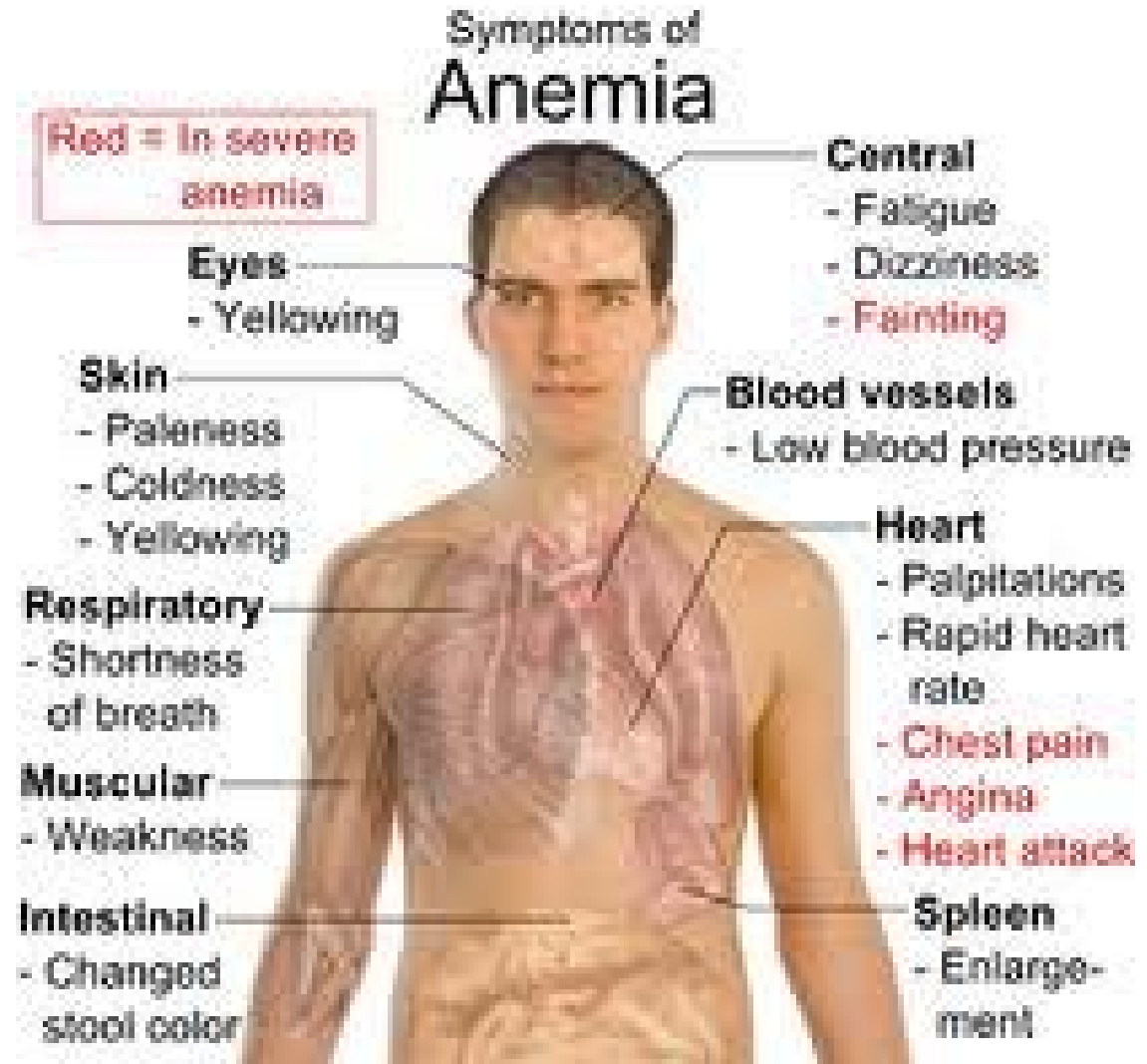


<http://t2.gstatic.com/images?q=tbn:ANd9GcRws8-a1BpN86WCiY1sYhtW-CqfiCzfRjzBbyiaE3xQCgt-R-8tHg>



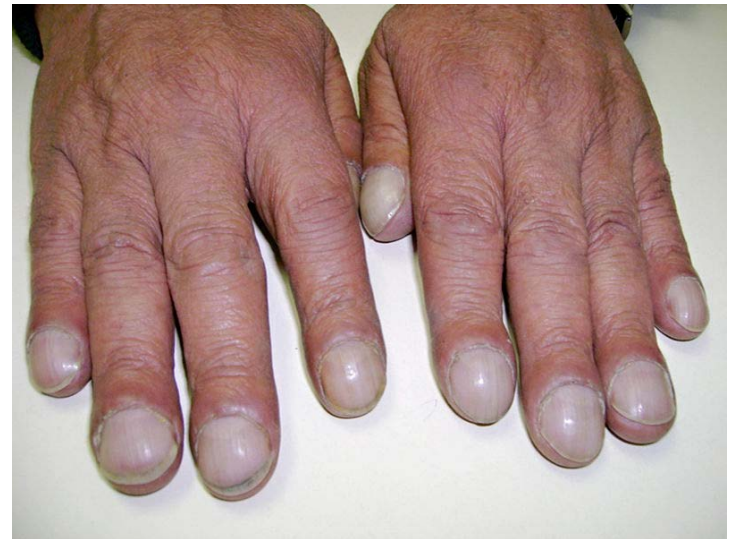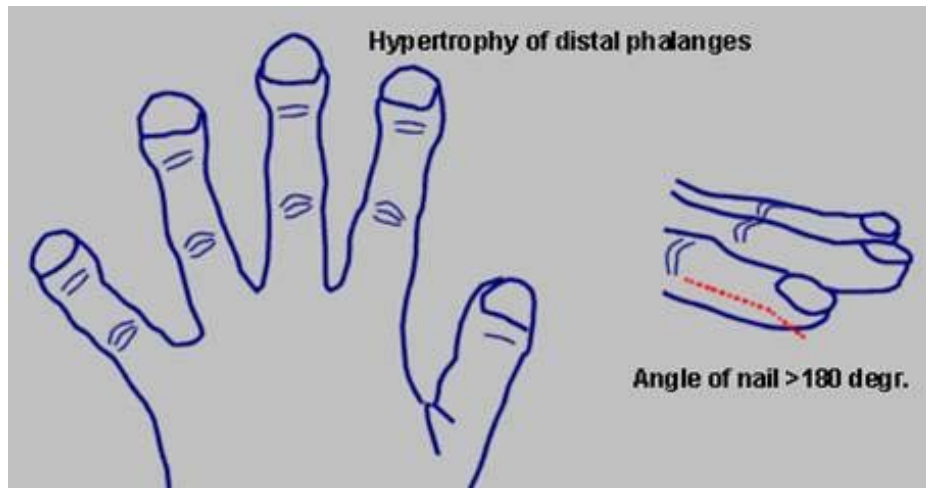
Inspection

- Cyanosis
 - Late indicator of hypoxia
 - O₂ sats < 85%
- Pallor (indicates anemia)



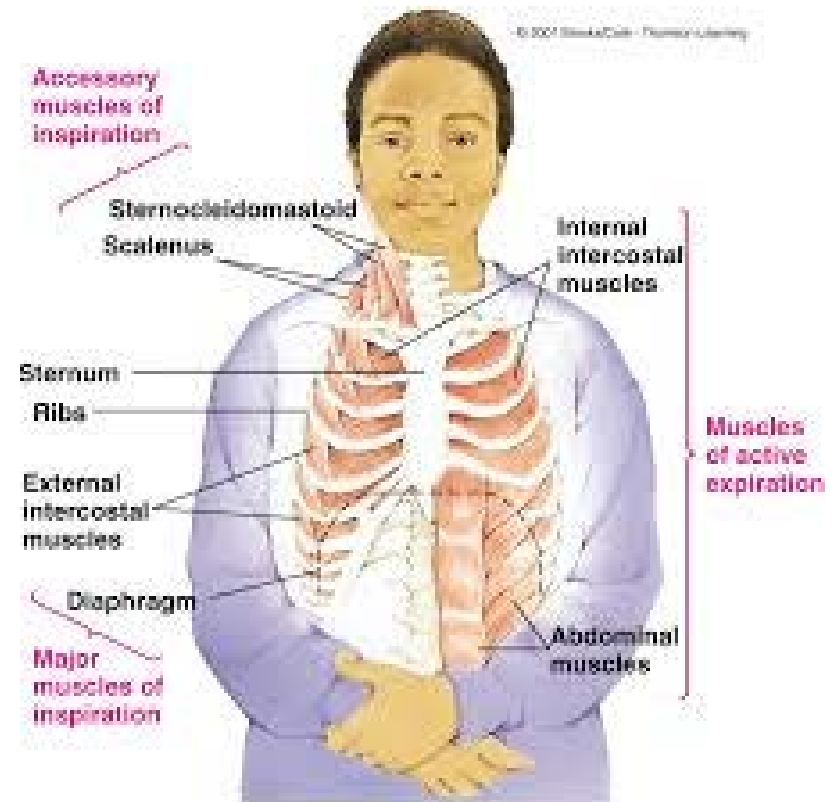
Inspection

- Assess for clubbing of fingers (associated with fibrotic lung disease, cystic fibrosis, congenital heart disease with cyanosis)



Respiratory Distress

- Respiratory Distress is indicated by exaggerations/aberrations of the normal respiratory pattern:
 - Barrel chest/enlarged A-P diameter as seen in COPD. Associated with prolonged expiration cycle.
 - Use of accessory muscles as seen in acute respiratory distress. (Retraction of intercostal muscles and contraction of the sternocleidomastoid muscles)

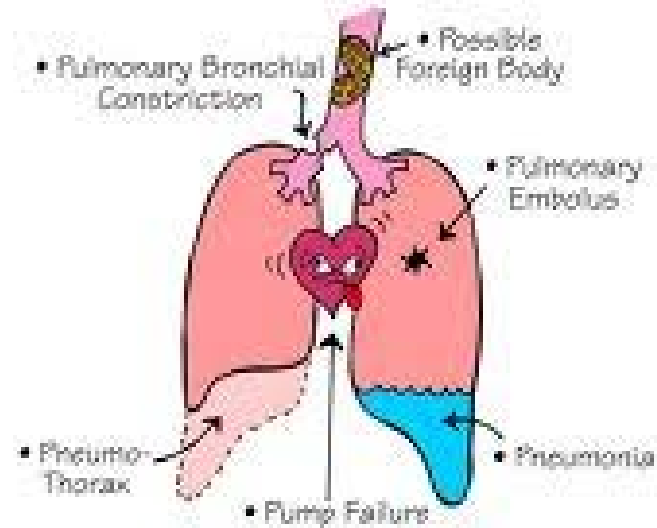


<http://www.google.com/imgres?q=use+of+accessory+muscles+for+breathing&start=87&authuser=2&hl=en&biw=1254&bih=645&tbn=isch&tbnid=TooMZZtnVBWMnM:&imgrefurl=http://www.sallyosborne.com/Lec%25203%25202013%2520Mechanics%2520of%2520a%2520Quiet%2520Breath.pdf&docid=BkGFjwlAwzID9M&imgurl=x-raw-image:///1554679b650c8a4e2bd2d0eb1ba32e3d1b11d16e7a46350906b8efb54af012e3&w=770&h=768&ei=G4JMUrmWOqnlYQhtmlGwDA&zoom=1&ved=1t:3588,r:2,s:100,i:10&iact=rc&page=5&tbnh=193&tbnw=194&ndsp=23&tx=122&ty=117>

DYSPNEA

- Difficulty breathing:
 - Associated with cardiac and respiratory diseases
 - Sudden onset in an otherwise healthy individual could indicate Pneumothorax
 - Sudden onset in ill/post op individual could indicate Pulmonary Embolism

6-P'S OF DYSPNEA

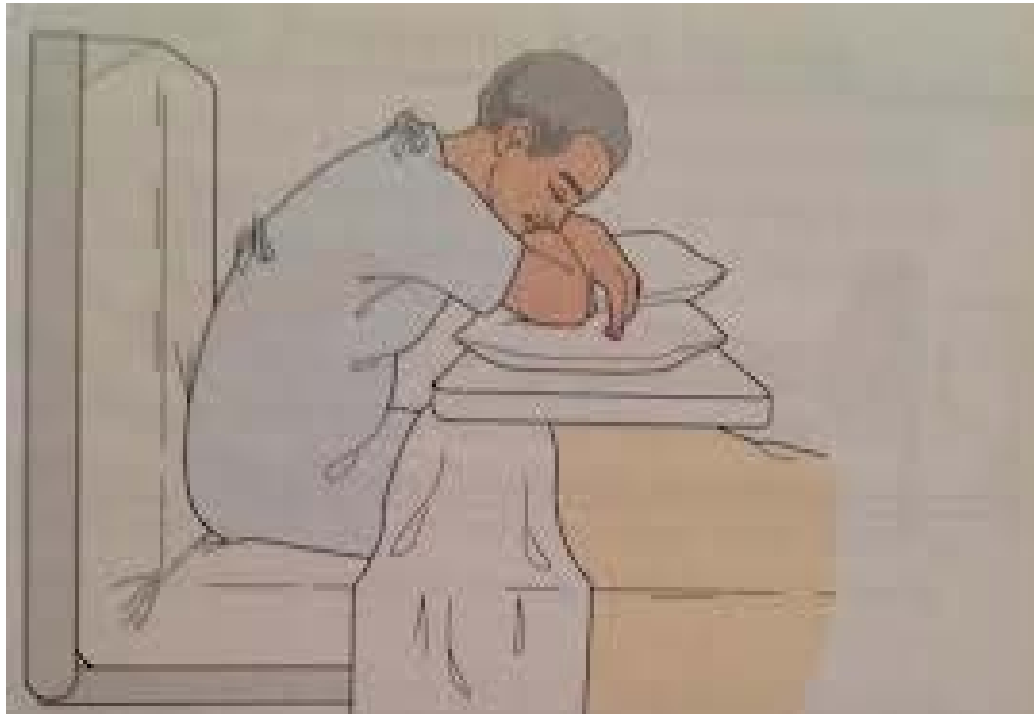

© 2007 Nursing Education Consultants, Inc.

http://www.google.com/imgres?q=dyspnea&authuser=2&hl=en&biw=1254&bih=645&tbn=isch&tbnid=TO_AWds1ao48DM:&imgrefurl=http://studentnurses3.blogspot.com/p/assessment-mnemonics.html&docid=UVNuF3hgDeTkM&imgurl=http://1.bp.blogspot.com/-bn0IwbV4kgo/TycvDH62mSI/AAAAAAAAA0k/Sg1mTy6rR14/s1600/Six%252BPps%252Bof%252BDyspnea.jpg&w=1600&h=1200&ei=k4JMuvqha_GWyAGYulG4DA&zoom=1&ved=1t:3588,r:5,s:0,i:102&iact=rc&page=1&tbnh=194&tbnw=259&start=0&ndsp=11&tx=127&ty=80

Orthopnea

- Position of comfort to relieve dyspnea
- Associated with COPD/CHF



http://t1.gstatic.com/images?q=tbn:ANd9GcQ-P531zj6n32doqycotY_elcdBfTaDhwYZn8xZNbo6Qzn6fVLP

Significance of Sputum

Description of Mucus/Sputum:	Possible Significance:
Thick	Dehydration
Purulent, thick, green/yellow	Bacterial infx
Rusty colored	Strep or Staph infx
Thin	Viral infx
Bloody/Pink-tinged	Lung CA, TB
Pink-tinged, profuse, frothy	Pulmonary edema
Malodorous	Lung abscess

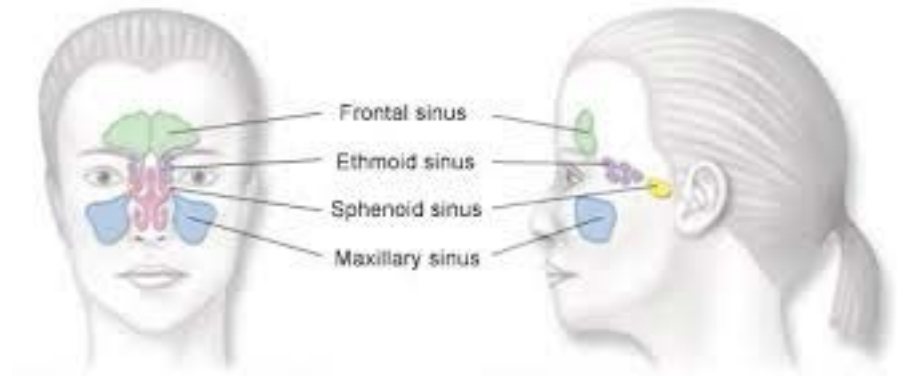
PALPATION

Purpose of Palpation

- Further assess abnormalities suggested by hx or inspection
- Assess skin and subcutaneous structures
- Assess thoracic expansion
- Assess Tactile Fremitus
- Assess Tracheal position

Palpation: General

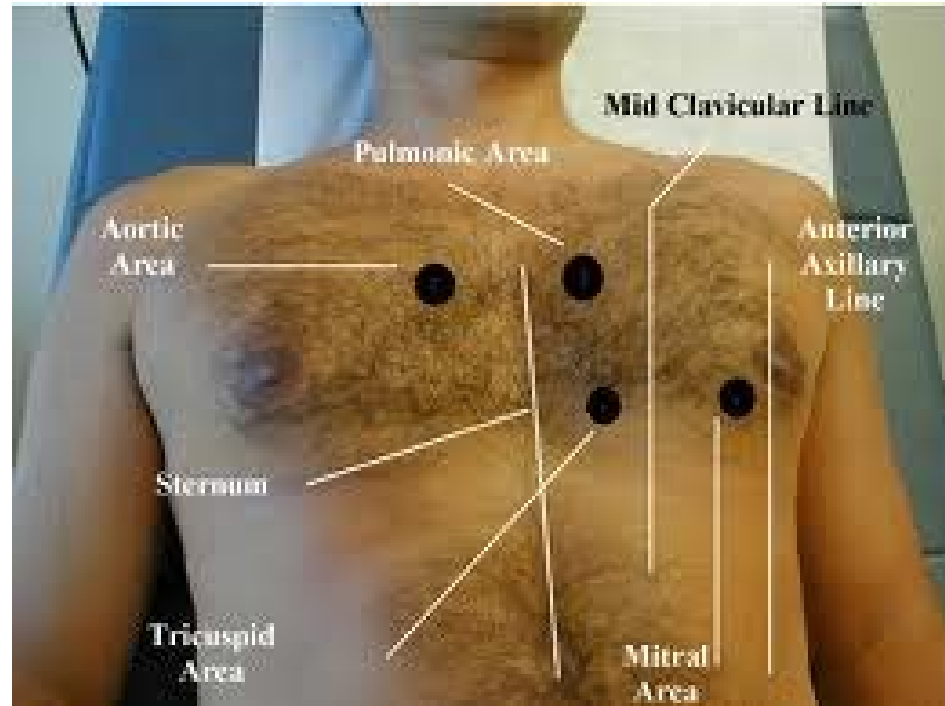- Assess Chest Wall for:
 - Tenderness
 - Masses
 - Lesions
- Sinuses
 - Palpate below eyebrow and at cheekbone
- Crepitus
 - Crackling (Rice Krispies) in SQ tissue



<http://t0.gstatic.com/images?q=tbn:ANd9GcSh0MX7xzMMeLAgBGwVi62b6HqhrqPDI5-Y-DaceqidRtOzBrBdkQ>

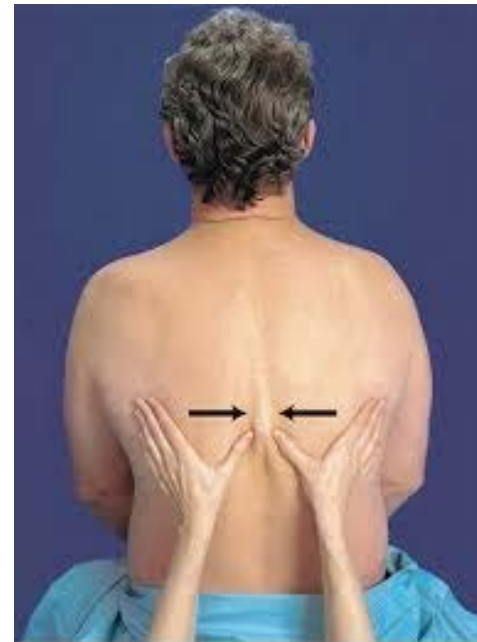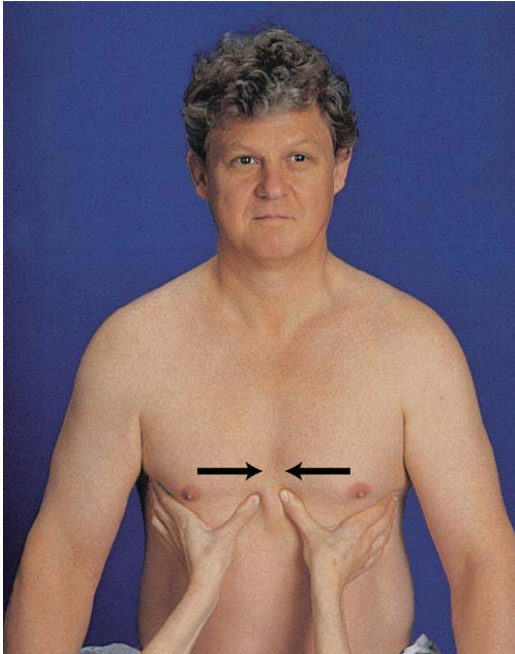
Palpation: General

- Chest Wall: Use palms of both hands simultaneously to assess symmetry
 - Assess for irregularities, tenderness
 - Crepitus indicates SQ emphysema (? pneumothorax)
 - Spine: straight/nontender
 - Sternum/xiphoid: fixed



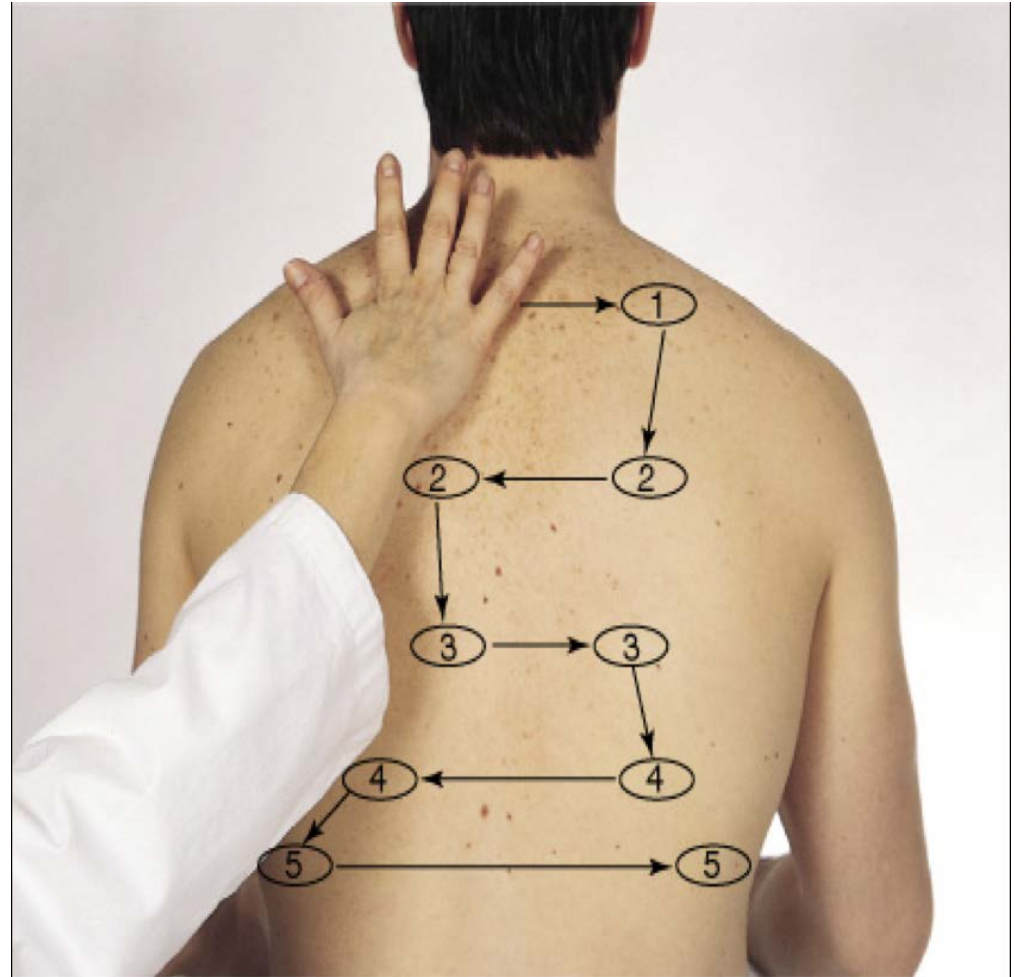
Palpation: Thoracic Expansion

- Thoracic expansion: should be equal bilaterally
 - Asymmetry: atelectasis, bronchiectasis, pleural effusion, pneumonia
 - Decreased expansion: emphysema, age related



Palpation: Tactile Fremitus

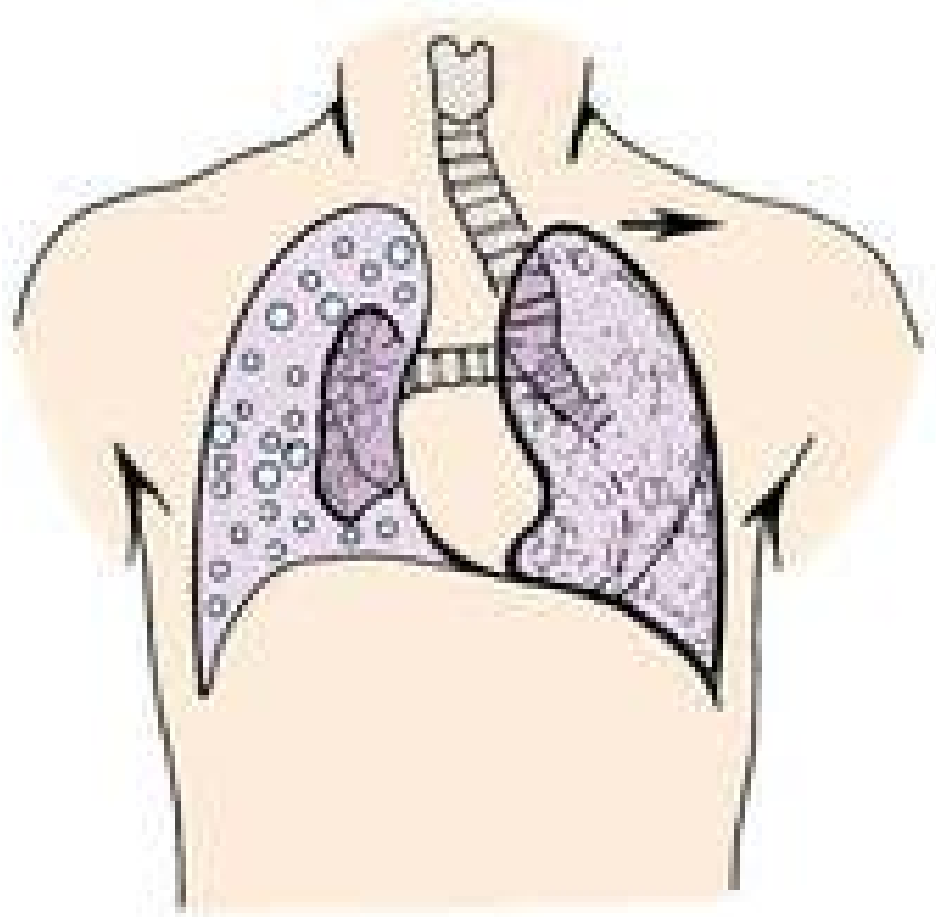
- Tactile Fremitus:
 - vibrations in the chest wall during vocalization (“99”)
 - Should be equal bilaterally
 - Decreased/absence: excess air in lungs as in emphysema, pleural effusion, pulmonary edema
 - Increased: pneumonia, tumor, fibrosis



Copyright © 2003, Elsevier Science (USA). All rights reserved.

Palpation: Tracheal Position

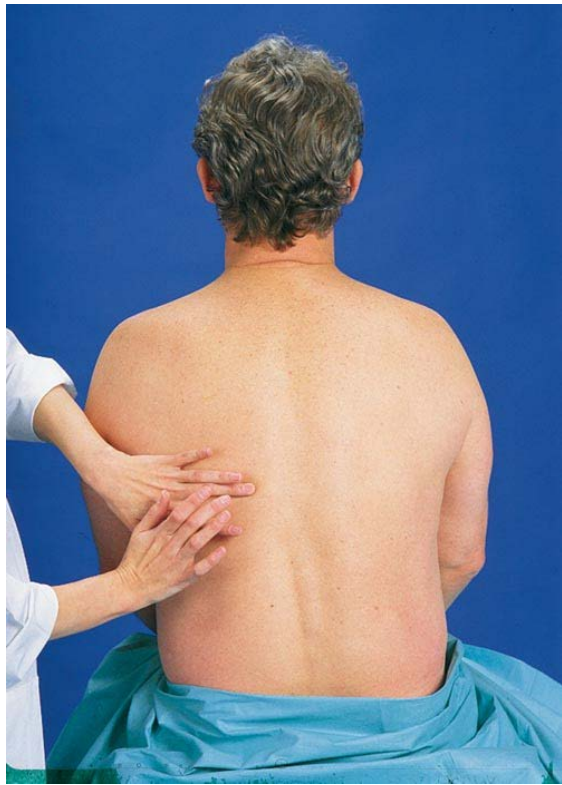- Tracheal position
 - Place finger on trachea in suprasternal notch and move laterally
 - Midline/equidistant between sternocleidomastoid muscles
 - **Deviation towards abnormal side:**
 - atelectasis,
 - pulmonary fibrosis
 - **Deviation towards normal side:**
 - neck tumors,
 - thyroid enlargement,
 - enlarged lymph nodes,
 - pleural effusion,
 - pneumothorax



PERCUSSION

Percussion

- The purpose of percussion is to determine if underlying tissue is filled with air or solid material.
- Avoid bony areas; use interspaces



biology-forums.com



webnetworksmd.com

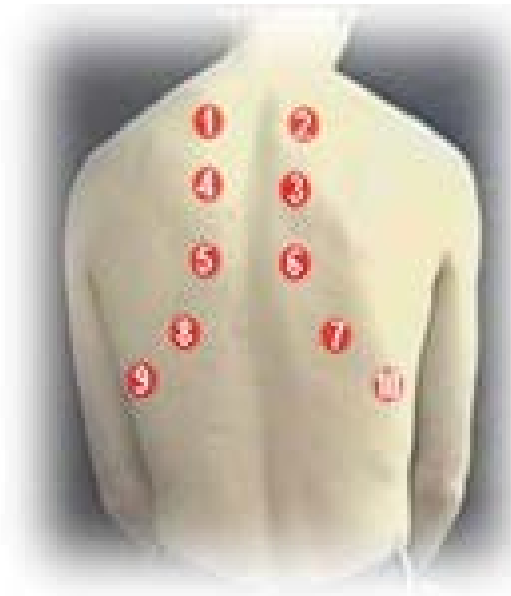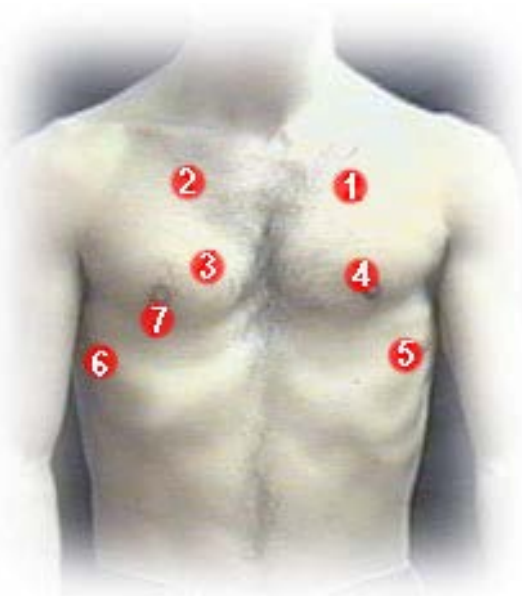
Percussion

- Normal: resonant/drum like sounds
- Flat/dull sounds:
 - Bone/muscle: flat sounds
 - Viscera/liver: dull sounds
 - Fluid/solid: pleural effusion, pneumonia, tumor
- Stomach: tympanic
- Hyper-resonant: Air trapped in lung; emphysema

AUSCULTATION

Auscultation

- Use the diaphragm of the stethoscope placed firmly against the body using systematic pattern
- Have patient breathe slowly and deeply through the mouth



Characteristics of Breath Sounds

Sound	I:E	Pitch	Intensity	Nl. Location	Abnl. Location
Bronchial	I<E	High	Loud	Anteriorly: Over trachea Posteriorly: upper right lung field	Lung area
Broncho-vesicular	I=E	Mod.	Mod.	Anteriorly: 1 st & 2 nd ICS at sternal border Posteriorly: between scapulae	Peripheral lung
Vesicular	I>E	Low	Soft	Peripheral lung	n/a

Adventitious Breath Sounds

Sound	Origin	Characteristics
Fine Crackles (Fr.: Rales)	Air passing through moisture in small air passages and alveoli	End of inspiration; non-continuous; not cleared by coughing; sounds like hair rolled b/t fingers
Medium/Coarse Crackles	Air passing through moisture in bronchioles, bronchi, & trachea	As above but louder; moister sound at early to mid-inspiration
Sibilant Ronchi/ Wheezes	Air passing through small air passages narrowed by secretions, swelling, tumors, etc (Asthma)	Continuous sounds; predominately in expiration; high pitched, musical, wheezing
Sonorous Ronchi/Wheeze d	Air passing through large air passages narrowed by secretions	Continuous sounds; predominately in expiration; clear with cough
Friction Rubs	Rubbing together of inflamed and roughened pleural surfaces	Creaking/grating quality; heard in I & E; heard best in lower anterolateral chest; no change with cough
Stridor	Partially obstructed trachea	Crowing sound

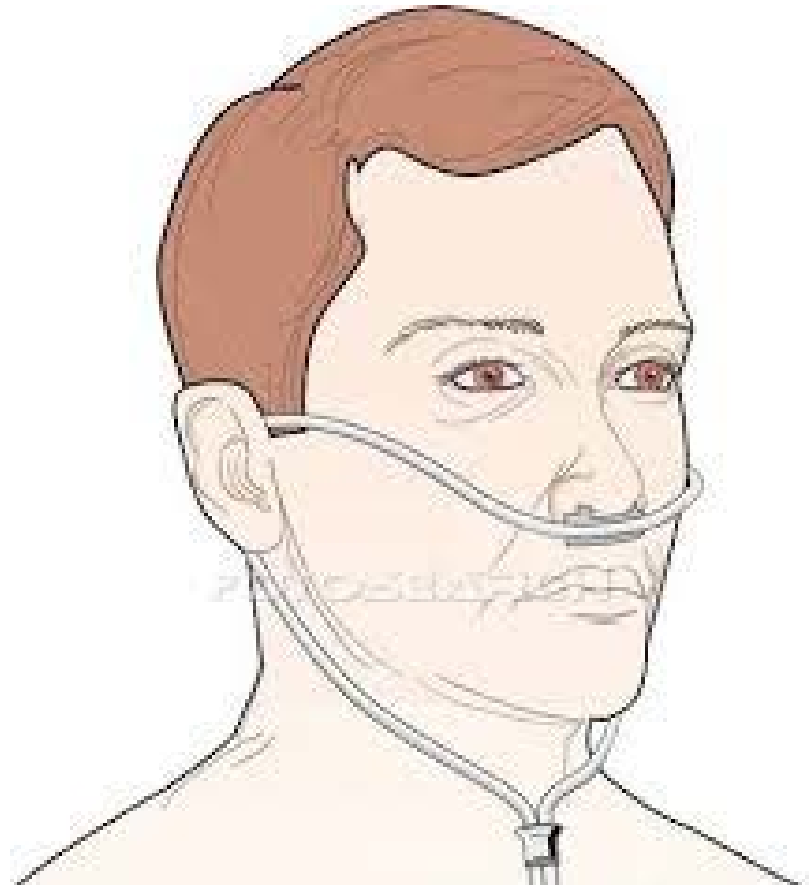
Assessment of Common Conditions

Condition	Inspection/ Palp	Percussion	Breath Sounds	Other
Consolidation	Guarding; expansion ↓	Dull to flat	↑ intensity	Inspiratory rales; friction rub
Pneumothorax	Trach shift	Hyperresonant	↓ or absent	-
Emphysema	↑ A:P diam.	Resonant/Hyp erresonant	↓ intensity	Sibilant ronchi; ↑ expiration
Pleural Effusion	↓ excursion	Flat to dull	↓ intensity	-
Atelectasis	Trach shift	Dull to flat over consolidation	↓ or absent intensity	Fine rales
CHF	Normal	Normal	Normal	Fine to medium rales at bases
Acute Bronchitis	Normal	Normal	Normal	Rales/ronchi/ wheezes

MISCELLANEOUS

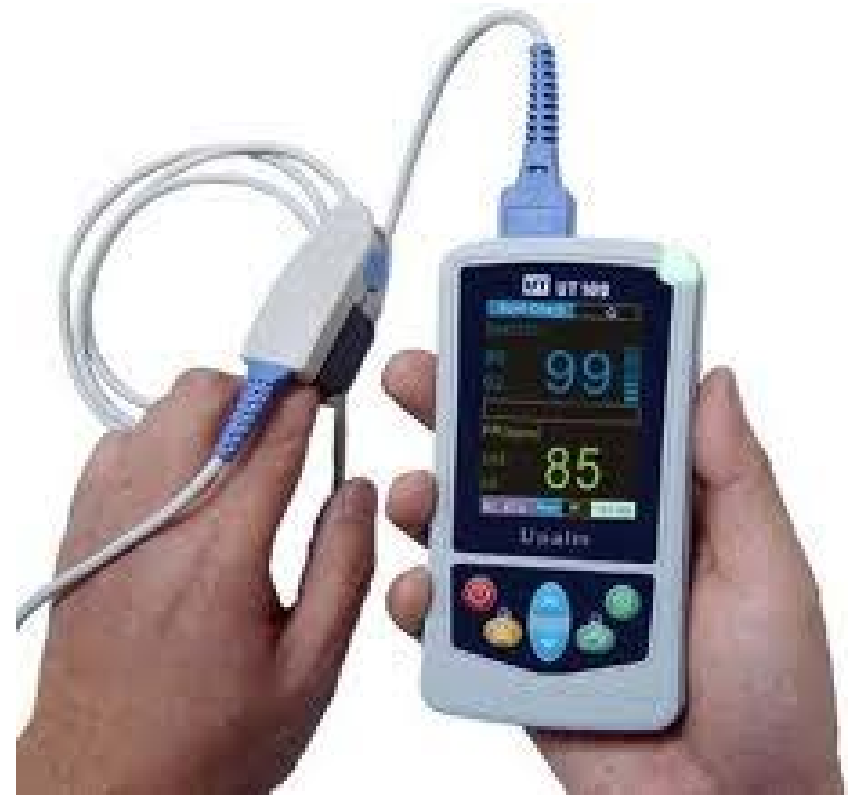O2 Administration

- O2 administration may be delegated to unlicensed staff
- PRN usage requires orders from the HCP with clear criteria for starting and stopping O2 therapy.
- Criteria must be objective (e.g., Pulse Ox $< 92\%$, Resp Rate > 26 , etc) and not based on nursing assessment (e.g., breath sounds)



Pulse Oximetry

- The photodetector distinguishes between the color of oxygenated and deoxygenated hemoglobin to determine the percentage of O₂ saturation.
- Normal – w/o COPD: 95-99%
- Normal – w/ COPD w/hypoxic drive: 88-94%



C-PAP/B-PAP

- C-PAP: Continuous Positive Airway Pressure therapy
- Indications: Obstructive Sleep Apnea
- Mechanism: increases air pressure in respiratory tree to prevent airway collapse
- Results: decreases daytime sleepiness, positive effect on heart health
- B-PAP: Bilevel Positive Airway Pressure: inspiratory PAP and a lower expiratory PAP for easier exhalation

